

COMMENTS TO AMR SEMINAR #57

CASE NO. 1 – CONTRIBUTED BY PHILIP ALLEN:

David Ben-Dor: Whatever it is, it looks very bland and (deceptively) benign. It's hard to say how well circumscribed it is- would need re-excision and careful follow-up. Maybe it will recur if not. My two cents for what they're worth.

Gerald Berry: I would defer to the soft tissue experts on this one! The lobulated pattern is not well developed and the inflammatory component is quite sparse in my section.

Michele Bisceglia: Agree with the diagnosis of ectopic inflammatory myxo-hyaline tumor.

Ira Bleiweiss: No idea what to call this, but I suspect it is malignant. I defer to the soft tissue mavens.

Tom Colby: Submitted as inflammatory myxohyaline tumor. This is out of my area but I would be concerned about a low-grade sarcoma here.

Kum Cooper: Thanks, Phil. Does not quite resemble the handful of cases I have seen in the correct location. My differential lay between a hybrid perineurioma-schwannoma; aneurysmal F-H tumor and myofibroblastic proliferation (fasciitis).

Ivan Damjanov: To me this tumor appeared like nodular fasciitis.

Otto Dietze: I agree, it seems to be a typical example of this entity.

Hugo Dominguez-Malagon: Difficult case, I do not know how to call it, looks myofibroblastic to me.

Göran Elmberger: Unfortunately soft tissue is not my strength. Learning about the entity is great. As far as I can see from the literature members in this group are dominating in publishing on this entity including the paper "Myxoinflammatory fibroblastic sarcoma: a tumor not restricted to acral sites" by Saul, Kum & Jenez et al 2002. As far as I can judge morphology is pretty characteristic for the suggested entity. In my practice I would do IHC, translocation marker t(1;10) and CGH/cytogenetics if possibly, mainly due to my lack of experience.

Vincenzo Eusebi: I think I would accept the diagnosis. There are also mummified cells.

Giovanni Falconieri: Thanks Phil. Impossible to comment, I would have hard time in recognizing "orthotopic" inflammatory myxohyaline tumor ...

Cyril Fisher: This is consistent with myxoinflammatory fibroblastic sarcoma. Non-acral examples are increasingly recognized – there are about a dozen in the literature.

Christopher Fletcher: Myxoinflammatory fibroblastic sarcoma (inflammatory myxohyaline tumour) seems as good a diagnosis as any for this unusual skin lesion on the shoulder. The lesion has a rather more prominent spindle cell component than most examples of this tumour type but, that being said, there are multifocally quite striking Reed-Sternberg-like cells as well as a mucin-containing pseudolipoblasts. In my experience, one may see very occasional cases at more proximal locations and I recollect seeing at least one similar case on the trunk.

Andrew Folpe: I think myxoinflammatory fibroblastic sarcoma in a non-acral location is a good diagnosis for this case.

Jerónimo Forteza Vila: I do not know the entity very well. I agree with the diagnosis, even though I also agree that the location is unusual for this type of tumor.

Masaharu Fukunaga: My impression was an unusual type of leiomyosarcoma. I agree with you, inflammatory myxohyaline tumor.

Allen Gown: Have no special insights into this tumor.

Thomas Krausz: This is difficult, I am not sure what this is. Inflammatory myxohyaline tumor is a great idea, but it looks less inflamed and nucleoli are not as prominent as in those examples I have seen before. I assume immuno did not reveal any other specific lineage of differentiation.

Janez Lamovec: Agree with the diagnosis myxoinflammatory fibroblastic tumor. Quite a substantial number of them are not acral; therefore, I wouldn't call it ectopic.

Thomas Mentzel: Histologically, an exophytic cellular fibrohistiocytic neoplasm with focal myxoid stromal changes and associated inflammatory cells is seen. Tumour cells contain enlarged and vesicular nuclei, and some mitoses are noted. Probably the lesion represents a superficial example of myxoinflammatory fibroblastic sarcoma.

Michal Michal: I would not diagnose it as "myxoinflammatory fibroblastic sarcoma", in spite of the fact that some features are present. There is absent the emperipolesis, which is always (sometimes very inconspicuously) present in the myxoinflammatory fibroblastic sarcomas.

Markku Miettinen: Because of presence of solid sheets of atypical cells and atypical mitoses, I prefer superficial myxofibrosarcoma variant (low-grade). Some resemblance to myxohyaline tumor must be admitted, but I don't think it is the same tumor.

Liz Montgomery: Inflammatory myxohyaline tumor/ myxoinflammatory fibroblastic sarcoma seems fine to me. Good example of why the WHO dropped the "acral" from acral myxoinflammatory fibroblastic sarcoma in 2002!

Santiago Ramon y Cajal: I would agree with you. It's a smart diagnosis.

Juan Rosai: I would go along with Phil's diagnosis of "ectopic" inflammatory myxohyaline tumor. I seem to remember some cases of this conditions having been reported in sites other than the distal extremities. If this entity did not exist, I suspect this case would have been placed into the category of low-grade myxofibrosarcoma (which it would not have been a dreadful mistake).

Joshua Sichel: Pleomorphic sarcoma with myxoid features. I haven't seen enough examples of inflammatory MHT to comment.

Dominic Spagnolo: I would accept this as a (non-acral) acral myxoinflammatory fibrosarcoma Phil. There are now a few of these reported in non-acral sites (including some reported by Kum, Janez and Saul a few years back).

James Strauchen: Yes, myxoinflammatory fibroblastic sarcoma (inflammatory myxohyaline tumor). Nice case!

Saul Suster: This does not quite look like the examples I've seen so far for this entity. My first thought when I looked at the slide was an atypical fibroxanthoma (AFX). Did you try a CD10? Said to be positive in the majority of cases....

Larry Weiss: I think it fits quite well for a myxoinflammatory fibroblastic sarcoma (what I like to call it). Interesting location.

Bruce Wenig: The histology fits and given reports, albeit rare, involving extra-acral sites, I certainly could accept the diagnosis of inflammatory myxo-hyaline tumor of the shoulder/back but would defer to the soft tissue experts.

Eduardo Zambrano: Although it is not the classic location or age group, I think I would have favored an interpretation of grade 2 myxofibrosarcoma, given the vascular pattern in this lesion. Nice Reed-Sternberg-like cells, though. In case of doubt, or in atypical locations like this, would looking for t(1;10) help in establishing a diagnosis of myxoinflammatory fibroblastic sarcoma?

CASE NO. 2 – CONTRIBUTED BY CARLOS BACCHI:

Phil Allen: Microcystic stromal tumor, ovary. I agree that it looks exactly the same as the cases in Irving and Young's recent paper. I wonder how many now believe that every tumor has been "discovered." One of my pathology teachers (now deceased) asserted that surgical pathology was completely worked out over 50 years ago. He was an experimental pathologist who liked to belittle diagnostic surgical pathology as a pastime for the late afternoon, after all the rats had been killed.

David Ben-Dor: Very interesting. The cells look monotonous like in carcinoids; in some places there is some cytoplasmic eosinophilia which brings to mind the possibility of luteinization. However the immunophenotype is against follicular origin. Is CD10 usually positive in ovarian stroma (and not just in endometrial stroma?)

Gerald Berry: The morphology and the immunostaining profile support the diagnosis of microcystic stromal tumor. My slide lacked the focal marked atypia that can be found in 60+% of cases.

Michele Bisceglia: Microcystic stromal tumor of the ovary. I was not aware of this entity. Thank you, Carlos.

Ira Bleiweiss: A new dx for me. I would add granulosa cell tumor to the differential.

Tom Colby: Submitted as microcystic stromal tumor of the ovary. Agree with diagnosis.

Kum Cooper: Thank you, Carlos, for sharing this new entity of microcystic stromal tumor with us. I recognized this tumor from the Bob Young paper that appeared last year in AJSP. I saw a good deal of sclerosing stromal tumors in Africa; but have not seen a bone fide case here in North America!

Ivan Damjanov: I checked the reference you gave in your write-up and indeed that's it. Never seen one, but this is a very interesting tumor.

Otto Dietze: Thank you for this contribution. I probably have missed or forgotten the publication.

Hugo Dominguez-Malagon: Microcystic stromal tumor of the ovary, a new one for me, thank you.

Göran Elmberger: Seems to be a perfect fit to Irving and Young's description. Thanks for a great case.

Vincenzo Eusebi: First case I have seen (recognized) of microcystic tumour of the ovary.

Giovanni Falconieri: Very nice case, Carlos. I agree with your interpretation. Thanks for this contribution.

Cyril Fisher: Microcystic stromal tumor of ovary as described, a rare tumor indeed.

Christopher Fletcher: Thanks ... – I have not previously encountered an example of this unusual ovarian tumour recently described by Robin Young.

Andrew Folpe: I confess that I had not read that paper. It seems a good fit. I was thinking "sex cord stromal tumor" of some type- the pattern reminded me of granulosa cell, but the cytology was obviously wrong.

Jerónimo Forteza Vila: An interesting case, unilateral lesions of benign behavior with absence of elements that suggest germinal cells and/or teratomatous cells. The reticular micro-cystic pattern, as well as CD10 and vimentin positive support the diagnosis.

Masaharu Fukunaga: It looks like yolk sack tumor or sclerosing stromal tumor. Thank you very much for the novel tumor, Carlos.

Allen Gown: Obrigado for this case, Carlos.

Thomas Krausz: I have read the paper and I agree that the features of the submitted case are those of microcystic stromal tumor of the ovary. As the line of differentiation is only "probably" stromal, we have to wait and see whether future work will clarify this further. I haven't seen such a tumor before.

Janez Lamovec: I was thinking of some type of ovarian stromal tumor and not a step higher. I didn't know of the entity.

Thomas Mentzel: Many thanks for sharing this most recently described ovarian stromal tumour.

Michal Michal: Typical case of microcystic stromal tumor of the ovary. Recently I saw a case of this tumor with heavy atypical cellular changes.

Markku Miettinen: Agree that the case matches well with the recently described microcystic stromal tumor of the ovary.

Liz Montgomery: I had never seen such a lesion so thanks for educating me.

Santiago Ramon y Cajal: The microcystic component is striking. Thank you for this very interesting case.

Juan Rosai: This lesion sure looks like the cases of microcystic stromal tumor of the ovary the Irving and Young published recently. Actually, Robin was kind enough to send me slides of a case to photograph for the Surgical Pathology book which looks remarkably similar to yours (maybe it is the same). As a philosophical aside, I am beginning to wonder whether tumor splitting will ever end.

Joshua Sickel: Beautiful case, Carlos. I've never seen (or recognized) this tumor before.

Dominic Spagnolo: What a wonderful case of microcystic stromal tumor of the ovary, and completely new to me. Thank you.

James Strauchen: I was not familiar with this entity! Superficial resemblance to endodermal sinus tumor. Thanks!

Saul Suster: I checked the paper and, indeed, it's identical! Thank you for the nice contribution. Just a little bit envious for the ovarian pathologists who still have a virtual playground of morphology from which to create new entities! No IHC, EM, cytogenetics or molecular pathology yet in place to challenge anything anyone says in this field!

Larry Weiss: I had never seen this tumor before, so thank you for including it. It has very distinctive features.

Bruce Wenig: Looks exactly as described in the Irving and Young article. Thanks, Carlos.

Eduardo Zambrano: Microcystic stromal tumor of the ovary. I had only seen one previous case in a slide seminar presented by Dr. Young a couple of years ago.

CASE NO. 3 – CONTRIBUTED BY IRA BLEIWEISS:

Phil Allen: Syringomatous adenoma of the nipple. This case corresponds nicely to those in Peter Rosen's article (Am J Surg Pathol 7:739-745,1983). Thanks for the contribution.

David Ben-Dor: I also noticed the syringomatous features on picking up the slide- very nice example. Happy for the patient's sake.

Gerald Berry: Agree. Nice example.

Michele Bisceglia: Syringomatous adenoma of nipple. Nice case. As Dr. Eusebi pointed out in his recent article on "Rare entities of the breast ..." (Pathology, Jan. 2010; 41:48-56), since the lesion can recur, some people adopted the non-committal term of "syringomatous tumour".

Tom Colby: Submitted as syringomatous adenoma of the nipple. Agree with diagnosis, spectacular case.

Kum Cooper: Beautiful example of syringomatous adenoma of the nipple. Thank you, Ira.

Ivan Damjanov: Classical.

Otto Dietze: Like from a textbook!

Hugo Dominguez-Malagon: Syringomatous adenoma of the nipple, agree, nice case.

Göran Elmberger: Beautiful "textbook" case. This tumor is said to show perineural growth on occasion. There is often close apposition but to me not convincing perineural pattern in this case. Lots of nerves in areola... Looks a little like the case I presented as MAC of the tongue in a recent seminar. In the publication that followed we finally settled for "sclerotic sweat duct-like carcinoma" of the tongue.. Benign or low-grade malignancy??

Vincenzo Eusebi: Classical syringoid tumour of the nipple. Thank You. I prefer to call these lesions tumor rather than adenoma as recurrences are seen in not less than 50% of cases.

Giovanni Falconieri: Very difficult case, Ira. I often find proliferative lesions of nipple/periareolar tissue somehow weird. Thank you for this instructive case.

Cyril Fisher: Syringomatous adenoma of nipple. Nice slide.

Christopher Fletcher: Great example of syringomatous adenoma! In some areas, the squamoid features are subtle and difficult to detect.

Andrew Folpe: Nice syringomatous adenoma.

Jerónimo Forteza Vila: The syringomatous-like pattern with comma-like tubules that remind us of its skin counterpart favor this diagnosis.

Masaharu Fukunaga: Thank you very much for the beautiful case of syringomatous adenoma of the nipple. Last week I saw a case with sclerosing adenosis-like features.

Thomas Krausz: Beautiful example. Last time I saw such a case was over 20 years ago in professor Azzopardi's collection. In places, I find it difficult to determine whether some of the tubules represent a branch of the nipple duct or tumor (especially those which appears to have two cell types).

Janez Lamovec: Most characteristic example of this rare tumor. Thank you.

Thomas Mentzel: A nice example of rare syringomatous adenoma of the nipple representing an important differential diagnosis to tubulopapillary adenoma of the nipple and well-differentiated tubular carcinoma, many thanks.

Markku Miettinen: Agree on syringomatous adenoma of the nipple variant.

Liz Montgomery: Interesting case. It seems like this would be easy to mistake for a tubular carcinoma on a needle biopsy – except that you are right that the epithelium does not look like that of normal breast ducts.

Santiago Ramon y Cajal: This is a very nice example of syringomatous adenoma of the nipple.

Juan Rosai: Syringomatous squamous tumor of the breast. Within the confines of the Club, I would not dare to use the alternative term low grade adenosquamous carcinoma (P P Rosen), although to me the two entities look quite similar. The tubular structures look more like sweat glands than mammary ducts, but I have the impression that they arise from the galactophorous ducts and that they are undergoing some type of sweat gland metaplasia.

Joshua Sickel: Nice example for the teaching collection...thanks!

Dominic Spagnolo: Great example of syringomatous adenoma of nipple. Pretty rare! Thanks for the case.

James Strauchen: Ira's case.

Larry Weiss: It looked benign but was hard to categorize. Great diagnosis.

Bruce Wenig: Had a cutaneous adnexal appearance, at least to me. Nice case.

Eduardo Zambrano: Syringomatous adenoma of nipple. Nice example!

CASE NO. 4 – CONTRIBUTED BY KUM COOPER:

Phil Allen: Epithelioid sarcoma, proximal type, vulva. I have always regarded genuine epithelioid sarcoma (Enzinger) and so-called proximal type epithelioid sarcoma as two separate entities, a view supported by the different clinical features and behavior. I am reluctant to accept shared INI-1 immunohistochemical staining as a “unifier” of genuine epithelioid sarcoma, so-called proximal type epithelioid sarcoma, rhabdoid tumor(s) and atypical teratoid tumors. I have been repeatedly disillusioned by over-interpretations of new (and old) immunohistochemical findings.

David Ben-Dor: This case scares me- I was prepared to be on the lookout for epithelioid sarcoma in biopsies from the extremities of young adults but in the vulva of a woman this age? I would probably sign it out as large cell undifferentiated carcinoma given the positivity for cytokeratins and squamous markers. I wouldn't have thought of doing CD34. But once you think of the possibility you could order the genetic examination for confirmation. There seems to be a lot of neutrophils and leukocytoclasia - is this typical for this lesion?

Gerald Berry: A beautiful example of proximal type epithelioid sarcoma.

Michele Bisceglia: Epithelioid sarcoma, proximal type with loss of INI expression. Interesting case.

Ira Bleiweiss: Agree. Ugly.

Thomas Colby: Submitted as proximal epithelioid sarcoma. Agree with diagnosis.

Kum Cooper: My case.

Ivan Damjanov: First I thought that we are dealing with a poorly differentiated squamous cell carcinoma, but I agreed with your diagnosis.

Otto Dietze: I remember only one case in our files, presenting with disseminated metastatic disease.

Hugo Dominguez-Malagon: Epithelioid sarcoma proximal type, excellent case, thank you, Kum.

Göran Elmberger: Interesting case. Looks like an undifferentiated carcinoma. Stains like an undifferentiated carcinoma. Shows EM features (desmosomes; microvilli) like an undifferentiated carcinoma. But is a sarcoma... I guess the idea is that it's not derived from an epithelial surface but still that's difficult to me. Merkel cell sarcoma? Guess one needs to add to the large list of differential diagnoses for BFUM tumors. At least we got antibody BAF 47 on our IHC list. Commercial FISH probe for 22q11.23 yet?

Vincenzo Eusebi: I agree, consistent with epithelioid sarcoma, proximal type.

Giovanni Falconieri: Extraordinary and intriguing case. I would not have thought to ES of proximal type. I wonder how many people would go ahead and sign this just as poorly differentiated carcinoma, given the clinical presentation and the support of keratin staining? Me, for sure. By the way, it was nice to get together in Istanbul recently.

Cyril Fisher: Epithelioid sarcoma with appropriate immunophenotypes. The neutrophilic infiltrate away from the necrotic areas is unusual.

Christopher Fletcher: Nice example of proximal-type epithelioid sarcoma showing unusually prominent necrosis. Areas of this particular case could be confused very easily with epithelioid angiosarcoma, in the absence of immunostains.

Andrew Folpe: Agree- proximal type epithelioid sarcoma/ extrarenal rhabdoid tumor. It's interesting- the INI-1 data may actually be reviving ERT as distinct from PTES.

Jerónimo Forteza Vila: A difficult case; we can consider differential diagnosis with undifferentiated carcinomas or lymphomas. The deletion of INI-1, if consistent, is diagnostic.

Masaharu Fukunaga: I agree, Kum, I did not know the INI-1 deletion.

Allen Gown: Nice example of proximal type epithelioid sarcoma, and nicely documented.

Thomas Krausz: Great case, often a diagnostic challenge.

Janez Lamovec: Very similar to poorly differentiated carcinoma; and we saw a few of the latter showing some rhabdoid morphology but they had some more characteristic carcinoma foci.

Thomas Mentzel: A wonderful example of a superficially located proximal variant of epithelioid sarcoma.

Markku Miettinen: Poorly differentiated large cell carcinoma with glassy cell features. Degree of atypia and inflammatory background differ from epithelioid sarcoma. CK6/5 is also unusual. The evidence of specificity of INI1/SMARCB1 loss for epithelioid sarcoma may still be incomplete.

Liz Montgomery: Thanks for sharing this. I really like the INI1 for lesions like this one for which one frets about metastatic carcinoma.

Santiago Ramon y Cajal: Thank you very much Kum. Epithelioid sarcoma is a challenging entity mainly due to the differences in morphology one can encounter.

Juan Rosai: Nice example of the tumor that has been called the proximal type of epithelioid sarcoma. As usual, it has well developed rhabdoid features. I suppose an alternative term could be epithelioid sarcoma with rhabdoid features, in order to emphasize an important morphologic component indicative of a more aggressive behavior and to be able to include examples that are not proximal in location (which most of us have seen).

Joshua Sichel: Bizarre location. Also considered epithelioid angiosarcoma and inflammatory "MFH".

Dominic Spagnolo: Very convincing proximal type epithelioid sarcoma of the vulva. Thanks Kum.

James Strauchen: I must have admit, I would have gone down the garden path and called this metastatic carcinoma!

Saul Suster: I have very limited experience with "epithelioid sarcoma, proximal type". My thoughts when I saw this case were lymphoepithelioma-like carcinoma vs. metastatic poorly-differentiated carcinoma. From the descriptions I've read it seems like the whole concept of ESPT is still fuzzy and in development, and I would shy away from that diagnosis except under the strictest clinicopathologic and IHC setting. This is the kind of case for which clinical follow-up can sometimes provide interesting information. Not sure I would be willing to bet the farm on the INI-1 results either. Some of these cytogenetic translocations and molecular "signatures" are becoming less and less specific as time goes by – perhaps predictably!

Larry Weiss: Nice case.

Bruce Wenig: Cool case! The epithelioid appearance with large nuclei, vesicular chromatin and prominent nucleoli reminded me of lymphoepithelial-like carcinomas. Scattered rhabdoid cells would not fit for LEL-like carcinomas nor would the loss of INI expression.

Eduardo Zambrano: Epithelioid sarcoma, proximal-type. To the list of INI-1 negative tumors provided by Kum, we should also add (for now) choroid plexus carcinoma, renal medullary carcinoma, cribriform neuroepithelial tumor and a subset of non-rhabdoid pediatric undifferentiated sarcomas.

CASE NO. 5 – CONTRIBUTED BY IVAN DAMJANOV:

Phil Allen: Wilm's tumor with heterologous elements, diffuse anaplasia and eosinophilic globules, kidney, female aged 18. I don't know the significance of the eosinophilic globules. As I have worked exclusively in adult hospitals, I have only seen Wilms' tumors in slide seminars.

Gerald Berry: We have only occasionally seen these tumors in this age group. Nice example of diffuse anaplasia. I do not know the composition of the eosinophilic globules.

Michele Bisceglia: Anaplastic Wilms' tumor, biphasic pattern, with chondrosarcomatous differentiation. The eosinophilic bodies are hyaline bodies seen mostly in Kaposi's sarcoma but also in other neoplasms, both epithelial and mesenchymal (one of these is new entry represented by Michal's case of ovarian fibroma). Hyaline globules were also seen in the epithelial cells of the epididymis (Shah VI et al, Am J Surg Pathol. 1998 Aug; 22(8):990-6.). You asked "what is that material". Some people believe they are a by-product of red blood cells. However in 1996 we studied 25 cases of KS by electron microscopy and also focused on hyaline bodies (HB), and this is what we wrote without a definitive conclusion: "Furthermore we wish to make particular mention of HB since they are considered in a proper context nearly as a pathognomonic marker of KS. HB were described in light microscopy as homogeneous eosinophilic round bodies mostly within or even outside the cytoplasm of KS cells. At EM level their appearance is that of round intracytoplasmic inclusions, smaller than erythrocytes, very heterogeneous in size and in electron density as previously stated. They are never surrounded by a membrane whilst round or cup-like electron lucent structures are often visible at the periphery of each spherical body. Cytoplasmic HB remains puzzling with regard to their origin and importance. Owing to their frequent high electron density, HB have been regarded as an expression of erythrophagocytosis with the loss of electron density apparently denoting hemoglobin dissolution and the occasional presence of ferritin loaded lysosomes in the same cell substantiating such a hypothesis. Nonetheless HB are usually far smaller than erythrocytes, they do never show the biconcave profile commonly seen in red blood cells and do not appear to have a cell membrane. According to our view not even the occasional finding of hemosiderin does definitely prove erythrophagocytosis. In fact no ultrastructural evidence of phagocytosis has been observed in the cytoplasm of KS cells including HB bodies and HB have never been seen enclosed in heterophagosomic vacuoles. Moreover HB have never been observed in those conditions characterized by phagocytosis of red blood cell such as the infection associated hemophagocytic histiocytosis or in other hemophagocytic conditions such as the inflammatory response to a simple bruise. Typical HB have been reported in epithelioid bacillary angiomatosis which is due to Bartonella or Rochalimaea infection, and in various types of neoplasms." (source: Pathologica 1996; 88:8-17)

Ira Bleiweiss: Agree.

Tom Colby: Submitted as Wilms' tumor with heterologous elements and diffuse anaplasia. Agree with diagnosis. With specialized pediatric and soft tissue practice these days, I can't remember the last time I saw a Wilms' tumor on the hoof.

Kum Cooper: Wilms tumor with heterologous cartilaginous differentiation. The eosinophilic globules are no different to that seen in other sarcomas (to my understanding) and are thought to be effete red blood cells.

Otto Dietze: I have never seen heterologous differentiation in a Wilms tumor with a similar extent.

Hugo Dominguez-Malagon: Impressive case of WT with heterologous elements, than Ivan.

Göran Elmberger: Thanks for showing this case. Unusual but obviously occurring in this age group. Difficult to see epithelial differentiation in HE – biphasic? No clue to what the distinctive looking intracytoplasmic hyaline globules could represent. Renin??? Looks a little Russel-Dutcher like but Ig's would not be the first expectation of protein deposit.

Vincenzo Eusebi: Wilms tumour with heterologous elements.

Giovanni Falconieri: Very instructive case. I have no experience with WT. But I have great memories from the time shared in Turkey! Thanks for this contribution.

Cyril Fisher: Wilms tumor, striking chondroid component.

Christopher Fletcher: Beautiful example of Wilms' tumour at a relatively unusual age. By analogy with similar structures in other tumors, I would guess that the eosinophilic globules are lysosomal in nature but I am not aware of any hard data in this specific setting.

Andrew Folpe: High-grade malignancy with chondrosarcomatous differentiation. I'm having a hard time finding anything on my slide that looks like Wilms tumor.

Jerónimo Forteza Vila: We concur with the diagnosis and we agree that the age at which it presented itself is not usual. Perhaps, the study of the ultrastructure could help recognize the referred eosinophilic material.

Masaharu Fukunaga: Wilm's tumor. Blastoid changes are prominent. This is the first time I see a case of Wilm's tumor in this age group. The comment is very novel to me, thank you, Ivan.

Allen Gown: I have no idea!

Thomas Krausz: Agree with diagnosis. Regarding the eosinophilic globules (thanatosomes), there is a very interesting paper about their pathogenesis in various settings: Papadimitriou JC et al. "Thanatosomes": a unifying morphogenetic concept for tumor hyaline globules related to apoptosis. Hum Pathol 2000, 31:1455-1465.

Janez Lamovec: We saw an occasional case of Wilms' tumors in adults here, never with this degree of chondroblastic metaplasia. In regard to hyaline globules we didn't see them in Wilms' tumors but they occur in many different tumors and I wonder whether they have any diagnostic importance.

Thomas Mentzel: A nice example of Wilms tumour with tumour necrosis and prominent cartilaginous differentiation. Unfortunately, I'm not sure if I found the "right" "eosinophilic globules" – probably degenerative in nature ?

Markku Miettinen: Wilms tumor variant with heterologous cartilaginous differentiation seems to be the best diagnosis.

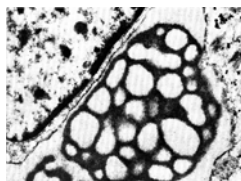
Liz Montgomery: This is a lovely Wilms' tumor. I do not pretend to know anything about the hyaline globules.

Santiago Ramon y Cajal: It is quite interesting to see this neoplasm in an 18-year-old. I wonder if anaplastic Wilms tumor behaves as bad in this age range as in younger children and of the biological significance of the important cartilaginous component, which can be seen after treatment. The globules in some areas remind me of hemophagocytosis.

Juan Rosai: Nice example of Wilms tumor, but with an amount of cartilage which is way in excess of what I am used to see in that tumor. I think some paediatric pathologists might have called this a teratoid Wilms' tumor. The fact that this patient is in an older age group for a Wilms tumor may have something to do with the abundant cartilage. It may be equivalent to the phenomenon seen in embryonal/botryoid rhabdomyosarcomas of the uterine cervix, which usually show only rhabdomyoblastic differentiation when seen in the usual age group but which often have plenty of cartilage when seen in patients in their twenties.

Joshua Sickel: Amazing case...thanks, Ivan!

Dominic Spagnolo: Agree with Wilm's showing heterologous elements. I don't know what the eosinophilic globules are but I have seen them as a focal finding in various malignancies, typically sarcomas, albeit uncommonly. I saw a striking example of these globules in the early '80s in a post-irradiation MFH which supervened on a juvenile nasopharyngeal angiofibroma. The protein globules immuno labelled for alpha-1-antitrypsin, and ultrastructurally they corresponded to intracisternal sieve-like arrangements of secretory material (Histopathol 1984; 8:339-352). I have sent an image, which is below, of the EM photomicrograph – I hope it doesn't contravene any copyright! Over the years similar globules have been reported in many different tumor types and I'm sure we have all seen them in different settings. But what, how or why, I don't know for most (giant mitochondria; endoplasmic reticulum whorls excepted). Case 14 submitted by Michal Michal has similar globules to profusion!



James Strauchen: Very nice example of Wilms tumor with heterologous elements. Thanks you!

Larry Weiss: Great case.

Bruce Wenig: Agree; not sure what the eosinophilic globules represent but they remind me of similar eosinophilic (hyaline) globules seen in the pancreatic solid and pseudopapillary neoplasm which are diastase-resistant PAS-positive, as well as being immunoreactive for alpha-1 antitrypsin. The globules in the pancreatic solid and pseudopapillary neoplasm may be part of a degenerative process and perhaps the ones seen in this case are too, although the origin/etiology of the globules in the pancreatic solid and pseudopapillary neoplasm are not truly known.

Eduardo Zambrano: Wilms tumor with heterologous differentiation. Very interesting case, in an unusual age group. The advanced age of this patient is an unfavorable prognostic feature, as is the diffuse anaplasia, which is associated with resistance to chemotherapy. Only a minority of Wilms' have mutations in WT1 (~25%), but mutations in this tumor suppressor gene are more commonly seen in tumors with heterologous differentiation like this case.

CASE NO. 6 – CONTRIBUTED BY OTTO DIETZE:

Phil Allen: Congenital granular cell tumor, buccal mucosa. We had one of these are about five years ago at Flinders Medical Centre, but I think it was the only one since the hospital opened in 1970.

David Ben-Dor: You're right- it looks just like the adult variant. Do the immunos reflect the possibility of this being derived from histiocytes and not from Schwann cells (the accepted progenitor in adults?)

Gerald Berry: Agree. A beautiful example of a congenital granular cell tumor.

Michele Bisceglia: Congenital granular cell tumor. Agree on the rarity of this tumor. We had just 2 such cases in 3 decades.

Ira Bleiweiss: Very nice granular cell tumor.

Tom Colby: Submitted as congenital granular cell tumor in a one-month old girl. Agree with diagnosis and appreciate the discussion.

Kum Cooper: I have always waited for one of these tumors to come to prove the S-100 negativity! Thank you.

Ivan Damjanov: I thought it was a granular cell tumor and learned from you that it was congenital. Nice, rare tumor.

Otto Dietze: My case, (meanwhile I have encountered another one).

Hugo Dominguez-Malagon: Granular cell tumor, congenital, nice example.

Göran Elmberger: Thanks- Indeed rare. Remember seeing one myself before but maybe our oral pathologists get them... Is it more bluish than adult type granular cell tumor?

Vincenzo Eusebi: Thank you for this nice example of congenital granular tumor.

Giovanni Falconieri: I thought of GCT but, as you, I am sure I have never seen it in such small babies.

Cyril Fisher: Congenital gingival granular cell tumor, nice example.

Christopher Fletcher: Perfect example of congenital granular cell 'epulis'. The line of differentiation in these lesions remains enigmatic but it increasingly seems that these 'tumors', which often regress spontaneously, may well in fact be some type of reactive process.

Andrew Folpe: I'm assuming this is the same as "primitive polypoid non-neural granular cell tumor"?

Jerónimo Forteza-Vila: A descriptive case. We concur with the diagnosis and comments.

Masaharu Fukunaga: I have never seen any case of congenital granular cell tumor. Thank you very much for the information of the immunohistochemical features.

Thomas Krausz: I have seen only one congenital form of granular cell tumor before. In the submitted nice example of congenital epulis there is very little mucosal hyperplasia in contrast to the adult, S-100 positive type.

Thomas Mentzel: A nice example of intraoral congenital granular cell tumour.

Markku Miettinen: Agree on (congenital) gingival granular cell tumor, non-neural.

Liz Montgomery: The cells have pretty big nucleoli – this reminds me of how alveolar soft part sarcoma sometimes looks when it presents in the mouths of babes. However, since cases reported as such have often behaved well, perhaps there is some overlap in these two entities in the literature. If you do a TFE3 immunostain it doesn't help since regular granular cell tumors and things called "epulis" also stain sometimes! It would be interesting to study a batch of such cases with FISH.

Santiago Ramon y Cajal: Thank you for this beautiful case of congenital granular cell tumor.

Juan Rosai: Very typical example of so-called congenital gingival granular cell tumor. The fact that this tumor, when occurring in this setting, is almost always S100 protein-negative supports the interpretation that not all granular cell tumors are neural, and that therefore the alternative term granular cell schwannoma is inappropriate. I think that the granular cell change is a lysosomal alteration of degenerative nature which can occur in a variety of cell types, usually but not only in Schwann cells. I have seen it in smooth muscle cells (otherwise typical uterine leiomyomas, with EM to prove it), epithelial cells, and cells of the dentigerous apparatus, as it has been suggested to be the case for the congenital gingival lesion exemplified by this case.

Joshua Sickel: Nice example. I've seen a few similar cases in the gingiva.

Dominic Spagnolo: Have never seen a congenital granular cell tumour and was not aware of the S100 negativity. Thank you.

James Strauchen: Also called "congenital epulis" to distinguish it from adult granular cell to which it is unrelated!

Saul Suster: Great case of granular cell epulis – hadn't seen one in quite a while!

Larry Weiss: Nice case. I wonder why it does not stain with CD68, since this is a lysosomal marker?

Bruce Wenig: Agree; I have seen two such similar cases but none recently. Thank you.

Eduardo Zambrano: Epulis. I hadn't seen one in a while.

CASE NO. 7 – CONTRIBUTED BY VINCENZO EUSEBI:

Phil Allen: ?Idiopathic hypertrophic cranial pachymeningitis, leptomenigeal spaces, foramen magnum, posterior fossa and bone with regression after steroid therapy. I have had no previous experience with such an intracranial tumor. It bears some resemblance to a hyalinized inflammatory myofibroblastic tumor.

David Ben-Dor: I'm impressed by the thick keloid-like collagen fibers but I'm not sure what this means. It's obviously very bland and hypocellular. There are also foci of whorling and of chronic inflammation. At least the boy is doing better with the therapy administered. By the way- congratulations on the new AFIP fascicle- haven't had the chance to go through it seriously but it looks very well done. It's about time we had a new edition. We were also looking forward to a successor to the classical Azzopardi- if this is it then we have two for the price of one!

Gerald Berry: I had not heard nor seen of this entity! Nice case. I pulled the original paper by Mamelak and do note that the photomicrographs exhibit more inflammation than I find on the slide.

Michele Bisceglia: Agree on your diagnosis. Never seen such a lesion in the meninges. A case of IgG4-related sclerosing pachymeningitis has most recently been reported also (first time) in intraspinal location by JKC Chan (AJSP August 2009). Vincenzo, you said your case was IgG4 negative: perhaps a paper I came across describing a similar lesion (involving the spinal dura) in association with retroperitoneal fibrosis may in any way be of interest to you (Tanaka T, Hamaguchi A, Kushima R, Okada Y. A case of renal pseudotumor associated with chronic pachymeningitis. *Int J Urol.* 1999;6:107-1010). Speaking of these meningeal-based sclerotic lesions, do not think your case is related to the dural-based lesion called "fibroosseous lesion" of the CNS of which I had the opportunity to see a case (Qian J, Rubio A, Powers JM, Rosenblum MK, Pilcher WH, Shrier DA, Stein BM, Ito M, Iannucci A. Fibro-osseous lesions of the central nervous system: report of four cases and literature review. *Am J Surg Pathol.* 1999;23:1270-1275.)

Ira Bleiweiss: No idea.

Thomas Colby: Submitted as idiopathic hypertrophic cranial packy meningitis. Agree with diagnosis. I have not seen this before; even that dramatic name does not give the degree of fibrosis in this case credit!

Kum Cooper: Vincenzo, what were the serum levels of IgG4? Did you try ALK-1 for IMT?

Ivan Damjanov: You are probably right—never seen anything similar.

Otto Dietze: Thank you, I was not aware of this entity before.

Hugo Dominguez-Malagon: It looks to me like a reactive process, there are foci of necrosis surrounded by plasma cells, an infectious agent should be ruled out.

Göran Elmberger: No, I have not seen a case like this. Excluding known etiological factors as infection, collagen vascular diseases, autoimmunity and taking the positive steroid response into account chances are that the lesion is some kind of inflammatory pseudotumor where burnt-out/non-representative lesions such as IgG4 sclerosing disease, R-D disease, LCH, sarcoidosis still may have been the explanation. S-IgG4? Multicentric disease in other organ systems?

Giovanni Falconieri: Incredible case, Vincenzo! Long name and impossible diagnosis. Thanks for this additional extraordinary contribution.

Cyril Fisher: Wow. I have no experience of the entity referred to (which is mentioned as having a granulomatous component). The response to steroids would fit, however. Is beta-catenin negative?

Andrew Folpe: Reminds me of what the head and neck people call "tumefactive fibroinflammatory lesion". Presumably some sort of "pseudotumor", representing an exaggerated response to the prior infection.

Jerónimo Forteza Vila: Clinical course is fundamental to approach the diagnosis in this case. The primary lesion is often, in many cases, a cholesteatoma.

Masaharu Fukunaga: Idiopathic hypertrophic cranial pachymeningitis. I have never seen such a lesion. Thank you very much for sharing the very rare case.

Thomas Krausz: I am not sure about this case. Similarly to you, I would have also looked for IgG4 disease. I would also consider calcifying fibrous pseudotumor in my differential, however the calcification in the submitted case appears not psammomatous and I have never heard it occurring on the meninges.

Allen Gown: No, never seen a case of this.

Janez Lamovec: It seems to me as some kind of unusual fibromatosis with chronic inflammatory reaction; any relation with other idiopathic types of fibrosis (mediastinal, retroperitoneal, etc)?

Thomas Mentzel: It looks like fibrosing chronic inflammation, but I have no experience with this kind of disease.

Markku Miettinen: Agree on a reactive fibroinflammatory process, cannot further specify.

Liz Montgomery: At low magnification I thought this was a low-grade sarcoma but ended up thinking this was “fibrosclerosing disease” akin to retroperitoneal fibrosis. Too bad the IgG4 was negative but I am not sure what that means.

Santiago Ramon y Cajal: This is a very interesting case. I would include in my differential a calcifying fibrous tumor.

Juan Rosai: I would have happily accepted the diagnosis of idiopathic hypertrophic cranial pachymeningitis were not for the fact that Mark Roseblum (one of the sharpest neuropathologist in town) does not think it is. On the other hand, radiographically it was said to be typical of the condition, and microscopically there is mainly fibrosis with hyalinization (with a touch of chronic inflammation), and is therefore hard to see how one can escape from making that diagnosis, assuming that it is a real entity (somehow it does not sound like it).

Joshua Sickel: Never seen anything like this. Defer to the neuropathology experts.

Dominic Spagnolo: I have never seen anything like this in this site. It has the appearance of a sclerosing inflammatory pseudotumor, and I think the consideration of the hyperIgG4 syndrome was a good one. I know nothing about idiopathic hypertrophic pachymeningitis I'm afraid.

James Strauchen: Reminiscent of pulmonary hyalinizing granuloma!

Saul Suster: Pass!

Larry Weiss: I have no idea. I guess I also would have considered a fibrous meningioma.

Bruce Wenig: I wish I had something intelligent to say about this case other than it looks like a fibrosing lesion. Never even heard of idiopathic hypertrophic cranial pachymeningitis.

Eduardo Zambrano: Very interesting case. I was not aware of this entity. I was thinking along the lines of inflammatory myofibroblastic tumor/ calcifying fibrous pseudotumor.

CASE NO. 8 – CONTRIBUTED BY CYRIL FISHER:

Phil Allen: Sarcomatoid adrenocortical carcinoma, left adrenal, with rhabdomyoblastic metastasis in a regional lymph node, male aged 45. The rhabdomyoblastic differentiation is unequivocal. I wonder if the “lipoblasts” might be the pseudo-lipoblasts of adrenocortical carcinoma. Similar lipid filled cells resembling lipoblasts can also be seen in hepatocellular carcinomas. I agree with Cyril that origin from an adrenocortical carcinoma seems to be the most likely explanation.

David Ben-Dor: Obviously a very interesting case. The cells in slide A, after looking briefly at it and before looking at the handout, looked hepatoid. The large cells in slide B (again on cursory examination) look similar to those in A and I wouldn't have thought based on histological examination they were different tumors. It's interesting that the adrenocortical tumor cells are negative (as reported) for calretinin and inhibin which are usually positive in these tumors. Could this be considered an adrenal oncocytic carcinoma? - I had an adventure with a case of that entity some years ago. Michele Bisceglia took that case and together with some of his own published with Lawrence Weiss the definitive treatment of oncocytic tumors of the adrenal. Maybe this is the first example of adrenal oncocytic sarcomatoid carcinoma?

Gerald Berry: Agree.

Michele Bisceglia: Agree on the probable origin of this tumor from accessory adrenal tissue. Very interesting.

Ira Bleiweiss: Strikingly rhabdoid. Adrenal would appear to be the primary from what you say.

Thomas Colby: Submitted as ? sarcomatoid adrenal cortical carcinoma associated with metastatic rhabdomyosarcoma. Agree with diagnosis, I have no better offering.

Kum Cooper: Cyril, it certainly looks rhabdomyosarcomatous in the metastasis. Sorry I do not have an alternative suggestion. Was good to talk with you at the USCAP.

Ivan Damjanov: Carcinosarcoma of the adrenal. Perplexing, but your explanation of these peculiar changes sounds plausible.

Otto Dietze: Carcinosarcoma or sarcomatoid adrenocortical carcinoma arising in ectopic adrenal tissue is a convincing diagnosis.

Hugo Dominguez-Malagon: Extraordinary case of sarcomatoid carcinoma of the adrenal. Metastatic lymph nodes contain unquestionable rhabdomyosarcoma, strange but possible combination. Thank you.

Göran Elmberger: Difficult case. I guess sarcomatoid (-ous) adrenal carcinoma is one possibility even if I am also not convinced by morphology, IHC and the anatomical gross relationships. Tumor in this location always makes me wonder about some odd variant of AML-PECOMA. The epithelioid variant of AML has been described to have sarcomatoid dedifferentiation and malignant behaviour occur in up to one third of cases. SMA?, MITF-1? HMB-50? Deletion 16p? Renal translocation carcinoma with sarcomatous dedifferentiation??

Vincenzo Eusebi: A convincing case of sarcomatoid carcinoma with rhabdomyoblastic differentiation.

Giovanni Falconieri: Very difficult and challenging. As long as my opinion matters, I agree that the prevailing phenotype is rhabdomyosarcomatous. Sorry, no alternative options.

Christopher Fletcher: What a remarkable case – I have never seen anything like this. Adrenocortical carcinoma with heterologous rhabdomyoblastic differentiation seems an entirely plausible explanation and it is very difficult to come up with any meaningful alternative.

Andrew Folpe: Very strange case. Oncocytic adrenal cortical carcinoma, with a small nodule of rhabdomyosarcoma, with the metastasis showing only rhabdomyosarcoma. How this relates to sickle trait I am not sure. Might be interesting to look for INI-1 loss in the adrenal- perhaps the adrenal counterpart of the medullary carcinomas seen in the same patients?

Jerónimo Forteza Vila: We agree that it is a mesenchymal tumor (sarcoma) with rhabdoid differentiation. Certainly, it resembles a previous case of ours. The origin in advance stages is difficult to ascertain.

Masaharu Fukunaga: This is a very tough case and beyond my understanding. The more I look the slides, the more I am confused.

Allen Gown: All I can say is, "Wow!"

Thomas Krausz: No better idea from me.

Janez Lamovec: Seeing the primary I also thought of extrarenal monotypic epithelioid angiomyolipoma (without angio and lipo component) but positivity of cells for myogenin and keratin and also general histological features are against this possibility.

Thomas Mentzel: To be honest I have no idea about the line of differentiation of the neoplasm shown in slide 8A.

Markku Miettinen: Adrenal cortical carcinoma in A, but metastatic (embryonal) rhabdomyosarcoma in B. So, the adrenal carcinoma probably had rhabdomyosarcomatous differentiation somewhere in that 24 cm tumor (perhaps in the central basophilic area in the primary tumor).

Liz Montgomery: Cyril, This case is quite something. I have no better idea than sarcomatoid adrenal cortical carcinoma with RMS differentiation.

Santiago Ramon y Cajal: I would agree with you favoring an adrenal origin. However due to the fixation artefacts, I wonder if some of the IHC results could be misleading. I would also have in mind in the differential a clear cell sarcoma.

Juan Rosai: I think a very good point has been made for this tumor to be an adrenal cortical carcinoma which so-called divergent differentiation along skeletal muscle lines. This case support the old saying that a malignant tumor in an adult patient having extensive skeletal muscle differentiation is more likely than not to be something other than a rhabdomyosarcoma. If any of you has the book edited by A Khan "Surgical pathology of endocrine and neuroendocrine tumors", please take a look at Fig. 6 on page 115.

Joshua Sickel: Another mind-blowing case. Adrenal origin sounds reasonable (and reportable!). The lesion looks very oncocytic.

Dominic Spagnolo: Extraordinary case Cyril and agree with your interpretation. The adrenocortical element is distinctly oncocytic. The metastatic rhabdo element is stunning.

James Strauchen: Pleomorphic rhabdomyosarcoma ? in sarcomatoid adrenocortical carcinoma.

Saul Suster: Too weird for me – this is definitely a case for Larry Weiss.

Larry Weiss: The histology of the bulk of the primary tumor is acceptable for an oncocytic adrenocortical tumor, and as you have cited, sarcomatoid areas may be very rarely seen. What was the mitotic rate in the non-sarcomatoid areas? Although also rare, one may see a stretched seemingly normal adrenal over an otherwise typical adrenocortical tumor (whether it is ectopic or actually coming from the gland, who knows).

Bruce Wenig: Wow, what a case! I have had the opportunity in my former life at AFIP to review lots of adrenal neoplasms but never one quite like this one. Given the information provided I believe a valid case can be made for adrenal gland origin for this neoplasm. The fascicle uses the designation carcinosarcoma and I am not sure that carcinosarcoma is not the best designation in this case. Thanks.

CASE NO. 9 – CONTRIBUTED BY CHRISTOPHER FLETCHER:

Phil Allen: Spindle cell lipoma with hibernoma cells, subcutis, nuchal region. I agree with Chris' interpretation that this is more likely to be a variant of spindle cell lipoma rather than a hibernoma. I have seen at least one of these before and interpreted it as a spindle cell/pleomorphic lipoma with hibernoma cells.

David Ben-Dor: I was impressed by the myxoid background and the prominent ropy collagen fibers. On close examination there are a few vacuolated fat cells scattered around (not many). Personally and especially given the location and demographics I find the possibility of spindle cell lipoma with brown fat differentiation attractive.

Gerald Berry: At low power I thought this was a spindle cell lipoma. It wasn't until I went to high power that I picked up the "hibernoma" cells.

Michele Bisceglia: Hibernoma, spindle cell variant. Do not recall having previously seen one.

Ira Bleiweiss: Agree.

Thomas Colby: Submitted as hibernoma, spindle cell variant. Sounds good to me. I suppose it is simply a twist of soft tissue fate that this case isn't called a spindle cell lipoma, hibernoma variant.

Kum Cooper: So I called this a nuchal fibroma and after reading your diagnosis went back to discover the hibernoma cells!!! I should have known better!

Ivan Damjanov: Nothing but to accept the diagnosis. I do not know how I would have called it! Something benign.

Otto Dietze: I have not seen this type of hibernoma and hibernoma in this location before, thank you.

Hugo Dominguez-Malagon: Agree Hibernoma, in my slide I see only the round cell component, no spindle cells are left.

Göran Elmberger: Thanks for the rare case and interesting discussion. Beautiful hallmark cell. High-resolution CGH and interphase FISH could be done on FFPE-tissues and as you mentioned in theory help distinguishing between hibernoma, spindle cell variant, and spindle cell lipoma with brown fat differentiation.

Vincenzo Eusebi: Very nice case. Thank you very much. The first one I've seen in a real slide.

Giovanni Falconieri: Never seen hibernoma before, Chris. Another beautiful collector's piece. Thanks for this educational contribution.

Cyril Fisher: Agree, spindle cell lipoma with hibernomatous areas is a good explanation for such comingled tumors in the absence of genetic data!

Jerónimo Forteza Vila: We concur with the diagnosis.

Andrew Folpe: Nice case. I'd probably label as a spindle cell lipoma with brown fat, given the location.

Masaharu Fukunaga: Hibernoma, spindle cell variant, it is new to me. These spindle cells are not prominent as hibernoma cells in the section. Thank you for the case.

Allen Gown: Lovely example; thank you, Chris.

Thomas Krausz: I like the idea of spindle cell lipoma with brown fat differentiation.

Janez Lamovec: I've never seen this before. Thank you.

Thomas Mentzel: What a nice case ! Given that in areas features of ordinary spindle cell lipoma with myxoid stroma, scattered mast cells and ropey-like collagen are present, I think that the lesion most likely represents a spindle cell lipoma with focal brown fat differentiation (similar as we can see it sometimes in ALT).

Markku Miettinen: Agree on hibernoma with a spindle cell component (spindle cell variant).

Liz Montgomery: When I first popped the slide up I could not figure out why someone would put a spindle cell lipoma in the seminar but the cute little brown fat cells were a nice little treat.

Santiago Ramon y Cajal: Very nice example of a spindle cell variant of hibernoma. Thank you for sharing this case with us.

Juan Rosai: Very nice example of hibernoma. It looked pretty classic to me, without a prominent spindle cell component in my section. The tissue is so fragmented as to suggest that it exploded through the transatlantic flight.

Joshua Sickel: Thanks for this rare collector's item...never seen this before.

Dominic Spagnolo: I prefer the idea of spindle cell lipoma with brown fat differentiation. Either way, have never seen this "mix"oma before, so thanks!

James Strauchen: Hibernoma! The current claim is that brown fat is actually related to skeletal muscle not fat.

Saul Suster: Agree with spindle cell lipoma with brown fat component.

Larry Weiss: Great case.

Bruce Wenig: As well as to head and neck (posterior part, in particular), too!

Eduardo Zambrano: I wasn't sure how to label this lesion, either as hibernoma or as spindle cell lipoma, as I wasn't aware of a spindle cell variant of hibernoma (or hibernomatous variant of spindle cell lipoma for that matter). I would assume that the spindle cell and floret cell components in this lesion are CD34-positive as in regular spindle cell lipoma. Is that a safe assumption?

CASE NO. 10 – CONTRIBUTED BY ANDREW FOLPE:

Phil Allen: Well differentiated retroperitoneal liposarcoma with focal dedifferentiation (not circled) and areas indistinguishable from spindle cell / pleomorphic lipoma. I have never been able to reliably tell the difference histologically between subcutaneous spindle cell / pleomorphic lipoma and deep well differentiated liposarcoma with spindle cell lipoma-like areas. Every time in the past I thought I could tell, I got it wrong so I now rely entirely on the tissue plane and boldly assert that all retroperitoneal and paratesticular spindle cell “lipomas” are under-diagnosed well differentiated liposarcomas, awaiting confirmation from long-term follow-up.

David Ben-Dor: On careful examination there are a few cells with irregular hyperchromatic (but not markedly enlarged) nuclei possibly out of the range of what is acceptable for WDL. I also found a few signet ring cell lipoblasts. But overall this is extremely bland. And people do needle biopsies of these masses (and believe the answers they get!). I thought that's why there are experts in soft tissue pathology for problems like this!! A few months ago I had a subcutaneous mass from near the jaw with what I thought were drop-dead lipoblasts and was surprised to get Chris Fletcher's reply of pleomorphic lipoma.

Gerald Berry: Agree. Nice case.

Michele Bisceglia: Spindle cell lipoma-like WDL. Thanks for contributing it and the update on CPM amplification in WDL.

Ira Bleiweiss: Spindle cell lipoma until one accounts for retroperitoneal location, therefore liposarcoma. As the real estate brokers say, location, location, location.

Thomas Colby: Submitted as dedifferentiated liposarcoma. Would call this liposarcoma; agree there are some spindle cell lipoma-like areas.

Kum Cooper: Andrew, what a wonderful case/finding! Fully agree with your sentiments.

Ivan Damjanov: Liposarcoma. My slide did not contain the dedifferentiated part or I did not recognize it.

Otto Dietze: I agree that this slide is indistinguishable from spindle cell lipoma, but with my limited experience I would never risk making this diagnosis in a retroperitoneal lesion and would favor WDL.

Hugo Dominguez-Malagon: I saw the case with no information and my diagnosis was spindle-cell lipoma, of course the retroperitoneal location goes with liposarcoma.

Göran Elmberger: Thanks for bringing up this important observation. I fully share your impression and do have similar experience from preparing a poster for 2010 USCAP on MDM-2 and CDK4 amplification in WDLPS/ATL. Furthermore, we had one case of spindle cell lipoma with “atypia” simulating WDLPS/ATL occurring on arm that did not show amplification so the reverse situation might also be true.

Vincenzo Eusebi: Thank you Andrew. I think you are right to be concerned. In a small biopsy it would be very difficult to establish the correct diagnosis.

Giovanni Falconieri: Very intriguing lesion, Andrew. Without knowing the history I would go exactly along your same lines. The circulating slide looks pretty much spindle cell lipoma. Obviously, in light of complete clinicopathologic details the story is different, and liposarcoma goes on the top of the differential. In somatic soft parts the diagnostic exercise can become further vexing. Retrospectively, and perhaps stretching a little bit my imagination, I could recognize some lipo/pseudolipoblast especially in the sclerosing areas.

Cyril Fisher: Spindle cell lipoma-like areas in WD liposarcoma/ALT. In this section there are also areas of WDL, particularly adjacent to and involving vessel walls.

Christopher Fletcher: To me, the lesion represented in this block shows much greater variation in adipocyte size than I would expect in spindle cell lipoma and at least a subset of the spindle cells have notably atypical hyperchromatic nuclei. Furthermore, although one may see occasional lipoblasts in spindle cell lipoma, they do seem more numerous in this particular slide than I would expect in that context.

Jerónimo Forteza Vila: We accept the diagnosis of lipomatous atypical/liposarcoma well differentiated, in the sample received. Clinical data are coincident; they are usually retroperitoneal tumors, truly gigantic and of difficult complete resection.

Masaharu Fukunaga: It really resembles spindle cell lipoma, but overall features indicate well-differentiated liposarcoma, sclerosing variant. If it is needle biopsy specimen, I may have problems. But the location is very important. Thank you very much for sharing the case, Andrew.

Allen Gown: Interesting speculation; thanks for the case, Andrew.

Thomas Krausz: Andrew, I fully agree with your comments, especially in view of the abundance of "ropey" collagen. I have never seen these spindle cell lipoma-like features in a well differentiated/dedifferentiated liposarcoma.

Janez Lamovec: Seeing it blindly, I wondered why you are sending a spindle cell lipoma to us. Then I read the text. One is always surprised by the richness of biological phenomena in general and by histological appearances of tumors in particular.

Thomas Mentzel: A very interesting case indeed! For me in the submitted slide, scattered enlarged and hyperchromatic nuclei as well as some lipoblasts are seen comparable with atypical spindle cell lipoma. Have you performed FISH for the deletion of Rb-1 gene? Probably the neoplasm represents a rare example of dedifferentiated spindle cell liposarcoma as discussed in Mod Pathol 2010; 23: 729.

Markku Miettinen: Well-differentiated liposarcoma. Would agree with some resemblance to spindle cell lipoma.

Elizabeth Montgomery: Yours truly HAS misdiagnosed an ALT/WDLPS as spindle cell lipoma on a needle biopsy of a slightly deep neck mass since it had a focus just like your retroperitoneal lesion. Our patient then had an excision and the lesion only had the one pocket that looked like spindle cell lipoma and the rest looked like ALT with no typical kinky collagen, etc for pleomorphic lipoma and it was shown to have MDM2 amplification. Luckily most cases follow the rules; obviously no one is going to call a giant mass in the retroperitoneum a spindle cell lipoma on a needle biopsy.

Santiago Ramon y Cajal: I agree completely with you. I have always had the same doubt that we base our diagnoses in location and not in morphologic features. With this morphology alone and no clinical history, the diagnosis would be extremely difficult. This highlights once more the importance of clinico-pathologic correlation.

Juan Rosai: I appreciate the points made about the fact that this tumor has many features reminiscent of a spindle cell lipoma (including "ropey" collagen) but it also has scattered atypical cells, some of them looking like pretty good for lipoblasts. Therefore I agree that this lesion is an atypical lipomatous tumor regardless of location. On the other hand, the similarities between this tumor and spindle cell lipoma remind me of the not often quoted paper by Azumi, Curtis, Kempson and Hendrickson (Am J Surg Pathol 11:161-183,1987), in which they suggested that atypical lipomatous tumor, spindle cell lipoma and pleomorphic lipoma are under the same umbrella, an interesting idea which however is not supported by the karyotypic findings in these tumors.

Joshua Sichel: Except for scattered pleomorphic cells, looks very similar to spindle cell lipoma. Great case, Andrew!

Dominic Spagnolo: Déjà vue! In March this year we encountered a well differentiated lipoma-like liposarcoma of the iliopsoas region, containing nodules of spindle cell lipoma-like tissue (both morphologically and immunohistochemically: CD34+, CD99+, BCL2+) affecting less than 10% of the tumor, but without any high grade dedifferentiation. High level MDM2 and CDK4 amplification was found in both the spindled areas and adipocytic areas. Looks identical to this case. We waffled about low grade dedifferentiation but preferred to say there were spindle cell lipoma-like areas present. My colleague Irene Low who primarily dealt with the case, I think corresponded with Chris Fletcher about the case. Will be interested to hear the soft tissue gurus' views on this.

James Strauchen: Focus of atypical lipomatous tumor (resembling spindle cell lipoma) in dedifferentiated liposarcoma.

Larry Weiss: Interesting.

Bruce Wenig: The findings in this retroperitoneal case are very similar to the hypopharyngeal/laryngeal well-differentiated (lipoma-like) liposarcomas I have seen (and published) over the years, so my immediate bias was to that diagnostic consideration.

Eduardo Zambrano: Great case, and a nice sequitur to the previous one. Similar question: were the spindle cells in this lesion CD34-positive? I wonder if the similarities with spindle cell lipoma are merely morphologic or if there is expression of similar markers as well.

CASE NO. 11 – CONTRIBUTED BY JERÓNIMO FORTEZA VILA:

Phil Allen: Abdominal cocoon (idiopathic sclerosing encapsulating peritonitis). I had heard of it before. I think it must have been the case report in Pathology International 50:660-666, 2000 where I saw it. Thanks for this very instructive case.

David Ben-Dor: Despite the gross impression of miliary distribution on histological examination the thick subserosal collagen is actually diffuse and circumferential with flattened parallel fibers/bundles connecting the small nodular foci. It's not very thick but in vivo given that it completely surrounds the gut it would limit expansion and passage of food, in the way that pericardial fibrosis impairs blood flow to the heart. Maybe this is related to idiopathic sclerosing retroperitoneal fibrosis (which is not saying much, since obviously from the title no one knows what causes that either). This case reminds me of the case of Eusebi commented on earlier- it's interesting how similar issues can crop up in spontaneously contributed cases.

Gerald Berry: A terrific name for an otherwise unappetizing lesion!

Michele Bisceglia: Idiopathic sclerosing encapsulating peritonitis (abdominal cocoon). Thanks for focusing on this neglected entity.

Ira Bleiweiss: Wow. How weird. I've never heard of this before.

Thomas Colby: Submitted as idiopathic sclerosing encapsulating peritonitis (abdominal cocoon/AC). Agree with diagnosis, this is a new entity for me with an exceptionally appealing name.

Kum Cooper: Fascinating! Abdominal cocoon...never heard of it! Live and learn is all I can say.

Ivan Damjanov: Consistent with sclerosing encapsulating peritonitis as described in books. I have never seen anything similar.

Otto Dietze: Thank you for this teaching case, I have never heard about or seen this before.

Hugo Dominguez-Malagon: Abdominal cocoon. I wonder if the etiology of this condition could be a parasite that becomes hyalinized.

Göran Elmberger: New to me. Thanks. The nature of the nodular scars with keloid-like fibrosis and ball-like arrangement is somewhat reminiscent of burnt out nodular sarcoid in the lung. Schaumann-like calcifications?? Well I guess the histology does not really help for deciding about etiology in this case.

Vincenzo Eusebi: Thank you, the first case I've seen.

Giovanni Falconieri: Nice case. Thank you for submitting another example of non-neoplastic GI pathology, a subject neglected by several colleagues in my practice. The pictures are outstanding!

Cyril Fisher: A rare and strange case. Agree with diagnosis. The few examples I have seen have been associated with previous surgery or other conditions.

Christopher Fletcher: This is a very instructive case for me since I had not previously been aware of this 'entity'. The discontinuous nature of the densely hyalinized fibrous tissue is quite surprising, as is its band-like (rather than mass-forming) distribution. The appearances seem quite different from sclerosing mesenteritis/sclerosing lipogranuloma.

Andrew Folpe: Very interesting. Never heard of it. Sounds nasty- "abdominal cocoon".

Jerónimo Forteza Vila: Our case. Do you agree with our diagnosis?

Masaharu Fukunaga: Idiopathic sclerosing encapsulating peritonitis (abdominal cocoon). Thank you very much for the rare lesion. I sometimes have autopsy cases of sclerosing peritonitis due to peritoneal dialysis.

Thomas Krausz: Very nice example.

Thomas Mentzel: What is the explanation for the impressive subserosal collagen nodules resembling amyloid deposits ?

Markku Miettinen: Agree on peritoneal fibrosis.

Liz Montgomery: What a nice abdominal cocoon. Too bad no one knows why some unlucky patients form this pattern of response to their various injuries.

Santiago Ramon y Cajal: Striking and puzzling case of sclerosing encapsulating peritonitis.

Juan Rosai: Very impressive case, with an appropriately high-sounding diagnosis: idiopathic sclerosing encapsulated peritonitis. It reminds me a little bit of a case that I saw as a fellow with Dr. Ackerman, which was reported by Bill Black as multifocal subperitoneal sclerosis (Surgery 63:706-710;1968). The only danger is that by giving fancy names to lesions we fool ourselves into thinking that we understand them, when in fact we often don't.

Joshua Sickel: Another bizarre case. Never even heard of this one! Thanks for the great discussion and references.

Dominic Spagnolo: Clinically and grossly the findings seem appropriate for sclerosing encapsulating peritonitis. Morphologically there seems to be much overlap between this, calcifying fibrous pseudotumor and reactive nodular fibrous pseudotumor.

James Strauchen: I have never seen an example of this unusual entity. Thank you!

Saul Suster: Never heard of this before! It looks very distinctive morphologically.

Larry Weiss: Never heard of it. Very distinctive and vaguely keloidal. Thank you for the nice discussion.

Bruce Wenig: Yet another diagnosis I was completely ignorant of but no longer am. Thank you.

CASE NO. 12 – CONTRIBUTED BY ALLEN GOWN:

Phil Allen: Malignant fibrous histiocytoma, thyroid gland and voluntary muscle. I have never been convinced that the resurrection of pleomorphic rhabdomyosarcoma as an entity was any more of a scientific advance than the old name change from pleomorphic rhabdomyosarcoma to malignant fibrous histiocytoma. One might look more kindly on the noncommittal term pleomorphic myosarcoma in this case, which dodges the smooth/striated muscle difficulty, but once one starts to believe too much in immunohistochemistry, one would have to consider a name change for keratin positive malignant fibrous histiocytomas. As my namesake has hinted, and as I more openly affirm, this current case could conceivably be an anaplastic thyroid carcinoma which has played a few immunohistochemical tricks to confound the credulous.

David Ben-Dor: I agree that purely on histological grounds there isn't much that would make me think of skeletal muscle (unlike the adrenal case previously commented on) without the help of immunohistochemistry.

Michele Bisceglia: Pleomorphic rhabdomyosarcoma. Very lucid discussion. Thank you.

Gerald Berry: This is one of the few convincing cases of pleomorphic RMS that I have seen. Nice case.

Ira Bleiweiss: Agree.

Kum Cooper: Thanks, Alan. Your pre-IHC comment had me recall the days we did PTAH and MT to demonstrate the cross striations in the muscle belly.

Ivan Damjanov: I thought that this was a MFH but accept your diagnosis.

Otto Dietze: Convincing histology and diagnosis.

Hugo Dominguez-Malagon: I agree with rhabdomyosarcoma, nice case and pictures.

Göran Elmberger: Are there a few eosinophilic rhabdomyoblasts with ample eosinophilic cytoplasm? I could not find any cross striations and that is not expected. To me a good reminder to be open minded and have an algorithmic approach on working up BFUM-tumors...

Vincenzo Eusebi: Nice case.

Giovanni Falconieri: Great case, I am sure that I have seen a couple of this RMS variant some 20 years ago. At that time, immuno did not work very well since the methods were a little bit away from standardization, only myoglobin was tried and it was negative, and other antibodies such as myoD1 and myogenin were far from available in the market. Like in this case, the lesion affected the soft parts of the thigh/popliteal fossa and the patient was an elderly lady. Needless to say, I called it MFH but that happened "before I saw the light" at the first meeting with Chris Fletcher.

Cyril Fisher: Pleomorphic rhabdomyosarcoma, with good immunohistochemical confirmation.

Christopher Fletcher: Thanks Allen for this very nice case and discussion – thanks also for your tact in not utilizing outdated mystical terminology!

Andrew Folpe: Quite a case. I wonder how well the thyroid was sampled- I'd still wonder about an anaplastic thyroid carcinoma with rhabdomyosarcomatous differentiation.

Jerónimo Forteza Vila: A difficult and interesting case. The location of the tumor compels us to, first; consider the possibility of thyroidal anaplastic carcinoma. In cases like this, where the immuno-histochemistry profile suggests a different entity, the possibility of sarcoma would be the second option to consider.

Masaharu Fukunaga: Making a diagnosis of rhabdomyosarcoma, pleomorphic type, is very difficult on H&E. Thank you very much for the education case.

Thomas Krausz: Pleomorphic malignant neoplasm with broad differential. I agree that histologic features together with the immuno result are consistent with pleomorphic rhabdomyosarcoma.

Janez Lamovec: Pleomorphic sarcoma with rhabdoid features. Immuno is instrumental in such cases. In this area, of course, anaplastic carcinoma of thyroid is always a possibility.

Thomas Mentzel: A nice case of pleomorphic rhabdomyosarcoma arising in an adult patient that is, like spindle cell rhabdomyosarcoma in this age group, probably more common than previously believed (but still a rare diagnosis).

Markku Miettinen: Agree on pleomorphic rhabdomyosarcomatous differentiation, but carcinomas and sarcomas with heterologous skeletal muscle differentiation have to be ruled out.

Liz Montgomery: Thanks for this case. This lesion is more "MFH"ish than some such pleomorphic tumors that display skeletal muscle differentiation on immunolabeling.

Santiago Ramon y Cajal: Unusual location for a pleomorphic rhabdomyosarcoma. This is a difficult case, my first diagnosis was anaplastic carcinoma. I guess I would do additional keratins to rule it out.

Juan Rosai: It looks like an anaplastic undifferentiated malignant tumor at the H&E level. Because of the setting I would have favored a diagnosis of anaplastic thyroid carcinoma but I agree that the immunoprofile

points in the direction of a pleomorphic rhabdomyosarcoma. (Funny for me to say that after the comment I made on Case 8).

Joshua Sickel: Agree with diagnosis. Weird clinical presentation.

Dominic Spagnolo: I can accept this as a pleomorphic rhabdomyosarcoma – it certainly looks like one though unusually paucimitotic and with an inflammatory background. There are some questions however that always arise in my mind with this type of pleomorphic sarcoma. Is the presence of such focal (really, limited) myogenin staining sufficient to categorize it as rhabdomyosarcoma, given that desmin and muscle specific actin are not a specific markers? Is the presence of just scattered cells positive for the putatively specific markers myogenin and myo-D1 enough? Unfortunately, quantification is not provided even in the larger series of 38 PRMS in adults published by Fanburg-Smith and colleagues (Mod Pathol 2001; 14:595); though more than 50% of cases in their series were positive for one or more of the specific markers myoD1 or myogenin, there is no information on how many cells are positive. Should we be performing EM in these cases more often, to see if there really is sufficient evidence of at least attempted sarcomeric organization (though I understand the sampling limitations)? And especially as there is good ultrastructural evidence that some of these sarcomas may in fact be exhibiting more than one line of differentiation, as shown nicely by Brian Eyden in a recent study of one case which showed skeletal muscle, smooth muscle and fibrohistiocytic differentiation (Ultrastruct Pathol 2010; 34:42)? Is it now too easy to categorize what might really be an undifferentiated sarcoma, as pleomorphic rhabdomyosarcoma simply because a handful of screwed up cells decide to express myoid transcription factors?? There are other analogies to this, e.g. one doesn't call a CLL/SLL case mantle cell lymphoma simply because there are scattered lymphoma cells that are cyclin D1 positive (as does happen, and is probably under-recognized). I do accept that there are any number of counterarguments to what I have said, but just being the devil's advocate.....Nice case all the same – thanks!!

James Strauchen: I might have called this MFH, but if you do enough immuno, MFH are all something else!

Saul Suster: My initial impression was that of anaplastic thyroid carcinoma. Given the location, why could this not be an anaplastic carcinoma that is aberrantly expressing muscle markers? After all, aberrant differentiation (now commonly but incorrectly designated “dedifferentiation”) is a common phenomenon in poorly-differentiated, high-grade neoplasms.

Larry Weiss: Nice discussion.

Bruce Wenig: Agree with pleomorphic RMS. I would be a bit careful relative to excluding an anaplastic carcinoma of the thyroid on the basis of negative cytokeratin expression as thyroid anaplastic carcinomas are rather whimsical in their immunostaining, although they tend to be more consistently reactive for cytokeratins that thyroglobulin and/or TTF1.

Eduardo Zambrano: By flipping the condenser, I may have hallucinated some cytoplasmic cross-striations. Otherwise, this definitely requires the help of a panel of immunos.

CASE NO. 13 – CONTRIBUTED BY JANEZ LAMOVEC:

Phil Allen: Giant cell tumor, head of left fibula, female aged 17, with multiple pulmonary metastases one year after excision of the primary. Despite the patient's young age, I accept that this is a true giant cell tumor rather than an osteosarcoma. There is a small amount of well differentiated, histologically bland, bone associated with one of the metastases but this is an occasional finding in primary giant cell tumors of bone.

David Ben-Dor: Looks typical but obviously not in this location- thanks. I know that there are cases of reparative giant cell granuloma in the jaw can have an aggressive course despite a typical histological appearance. And there is also the phenomenon of “benign metastasizing pleomorphic adenoma”.

Gerald Berry: The ongoing argument of transport versus metastasis is exemplified by this case!!

Michele Bisceglia: Pulmonary metastasis of GCT of bone. Janez, this case reminded me of a similar case which I misinterpreted as “a solid variant of aneurysmal bone cyst”, which was reversed to a diagnosis of “GCT of bone with secondary aneurysmal cysts” when lung metastases came up.

Ira Bleiweiss: Agree. Classic example.

Thomas Colby: Submitted as pulmonary metastases of giant cell tumor (apparently prior to any surgical intervention on the primary). Agree with diagnosis, lovely example.

Kum Cooper: Thank you Janez. I always considered GCT of bone to be locally aggressive and have the potential to metastasize.

Ivan Damjanov: Agree. We have seen a similar case—1 in 15 years.

Otto Dietze: Thank you for this “educational” contribution, I did not see this “2%” complication in my practice before.

Hugo Dominguez-Malagon: Metastasizing giant cell tumor. No features distinguishable from regular GCT.

Göran Elmberger: Thanks for unusual and pretty case. Another “benign metastasizing...” Reminds us of the limitations with our morphological observational methodology.

Vincenzo Eusebi: Very nice case. Thank you Janez.

Giovanni Falconieri: Another example of a benign metastasizer to the lung, as a few other cases already circulating in the past. Thank you Janez. I guess I have already seen an example like this, perhaps at one of your seminars in Ljubljana or sharing cases in your office. I believe that it is still hard or impossible to predict which GCT is more prone to metastasize. It was good to meet each other again at the last Rywlin seminar.

Cyril Fisher: Beautiful example of metastatic giant cell tumour of bone, thanks Janez.

Christopher Fletcher: Great example of an uncommon phenomenon – it seems that the behavior of such ‘benign-looking’ metastases can sometimes be quite indolent.

Andrew Folpe: Benign metastasizing giant cell tumor of bone. Nice example. Thanks for contributing it.

Jerónimo Forteza Vila: We agree with your diagnosis; and we recognize the malignant behavior demonstrated. It is not habitual in this entity.

Masaharu Fukunaga: Thank you very much for the typical and beautiful case of multiple pulmonary metastases of giant cell tumor of bone.

Thomas Krausz: Highly educational case. Jan, thank you very much.

Janez Lamovec: My case. No progression of metastases so far.

Thomas Mentzel: Many thanks for sharing this rare metastasizing giant cell tumour of bone that represents, as its counterpart in soft tissue, a very low-grade neoplasm (intermediate locally aggressive rarely metastasizing).

Markku Miettinen: Metastatic giant cell tumor of bone – histologic appearance in the lung is bland, as has been the case in previous examples in my recollection. Seems to be often indolent.

Liz Montgomery: Thanks so much for this example of bland-looking giant cell tumor of bone that has spread.

Santiago Ramon y Cajal: I agree. It is always important to remember that giant cell tumor of the bone can metastasize.

Juan Rosai: Very nice case of so-called metastasizing “benign” giant cell tumor of bone to lung. I don't see how we can call these lesions “benign” on biological grounds. I think there are simply low grade metastases of low grade tumors, similar to the metastases of “benign” mixed tumors of salivary glands, “benign” cellular blue nevi, and “benign” uterine leiomyomas.

Joshua Sickel: I have never seen this phenomenon. Thanks for the great teaching case. I've seen one case of multiple pulmonary mets from a “benign” fibrous histiocytoma of subcutis.

Dominic Spagnolo: Nice example of metastatic giant cell tumour of bone. We have a few of these on file. Some of our patients are now receiving adjuvant treatment with Denosumab, with variable response, but as far as I am aware the data have not yet been published. In one stunning case, there was quite an amount of bone formation in the pulmonary metastases, leading to much introspection over the possibility that the primary may have been a giant cell rich osteosarcoma, but in was indeed a *bona fide* giant cell tumour.

James Strauchen: Very nice example of metastasizing giant cell tumor of bone! Thank you!

Saul Suster: I have a few cases like this in my pulmonary collection. They can be very persistent and continue to metastasize despite the indolent morphologic appearance. It appears that surgical excision is curative in these cases. Makes you wonder about how flimsy our definitions of “benign” and “malignant” really are.

Larry Weiss: Absolutely classic histology.

Bruce Wenig: I see so many of these lesions in the head and neck but unlike in this case they generally do not spread and they are as innocuous looking as this patient's case. Thanks.

Eduardo Zambrano: Metastatic giant cell tumor of bone. As is usually the case with these tumors, no histological features of malignancy that would have predicted the development of distant metastases can be identified in this particular case.

CASE NO. 14 – CONTRIBUTED BY MICHAL MICHAL:

Phil Allen: Ovarian fibroma with heavy deposits of hyaline globules. Hyaline droplets are illustrated on page 196 of Scully's third series Fascicle, “Tumors of the Ovary, Maldeveloped Gonads, Fallopian Tube and Broad Ligament.” These globules are similar to those in case 5 of the seminar, the Wilm's tumor with heterologous elements. Do I have enough evidence to argue that the two are related?

David Ben-Dor: I think Michal must have the record for the amount of intriguing unusual entities that he has uncovered!

Gerald Berry: Agree.

Michele Bisceglia: Ovarian fibroma with heavy deposition of hyaline globules. Thanks for submitting this case.

Tom Colby: Submitted as ovarian fibroma with hyaline globules. Agree with diagnosis. It is nice to see that hyaline globules are making a comeback among surgical pathologists. They were in vogue when I first started training. This is certainly hyaline globulinosi maximus.

Kum Cooper: Thank you, Michal, for this beautiful example of this recently described entity. It was good to see you at USCAP.

Ivan Damjanov: Nice. Maybe I'll see a similar case if I keep looking.

Otto Dietze: I agree, a possibly neglected entity within the spectrum of putative degenerative changes.

Hugo Dominguez-Malagon: No idea of the entity, thank you for the information, Michal.

Göran Elmberger: Thanks for the eye-catching case and excellent discussion. In WHO on Female Genital Tract 2003 pp 151 they mention eosinophilic droplets. As a hallmark lesion the hyaline globules are unspecific. A Medline search today found 264 articles including 22 reviews on this subject. A rather impressive table on different tumors where they occur can be found in an article on Thanatosomes by Silverberg. Obviously the composition of these globules is even more complex as witnessed by their broad occurrence and varying histogenetic composition. Still important clue or pitfall depending on awareness status...("Thanatosomes": A unifying morphogenetic concept for tumor hyaline globules related to apoptosis John C. Papadimitriou MD, PhD, Cinthia B. Drachenberg MD, David S. Brenner MD, Carnell Newkirk MS, Benjamin F. Trump MD and Steven G. Silverberg MD. Hum Pathol. 2001 Aug;32(8):894-5).

Vincenzo Eusebi: Another very nice case.

Giovanni Falconieri: Thank you Michal for submitting this educational case. I have never seen hyaline globules in a fibroma or other stromal ovarian tumors.

Cyril Fisher: Ovarian fibroma with hyaline globules, striking appearance.

Christopher Fletcher: I have not personally encountered this phenomenon in ovarian fibroma, but my experience with such lesions is quite limited. The nature of these eosinophilic hyaline droplets seems again to be enigmatic!

Andrew Folpe: Interesting. Were the globules actin positive?

Jerónimo Forteza Vila: We agree with your diagnosis.

Masaharu Fukunaga: Fibroma of the ovary with hyaline globules. I have not seen this type of ovarian fibroma. Thank you very much, Michal.

Thomas Krausz: This is the first example of ovarian fibroma with hyaline globules I have ever seen. Thank you very much. Regarding the histogenesis of the globules, like in case 5 above, I suggest the mechanism put forward by Papadimitriou JC et al, Human Pathology 2000; 31:1455-1465.

Janez Lamovec: These globules were described in so many different tumors that they have become of dubious diagnostic importance. We once saw them in multilocular peritoneal inclusion cysts simulating yolk sac tumor.

Thomas Mentzel: Thanks for this nice example of an ovarian fibroma with numerous eosinophilic hyaline globules.

Markku Miettinen: Fibrothecoma with unusual hyaline globules.

Liz Montgomery: Together with case 5 we are having a sale on hyaline globules. They are very pretty.

Santiago Ramon y Cajal: Very nice case. Thank you.

Juan Rosai: I agree with the diagnosis of ovarian fibroma with jillions of hyaline bodies ("thanatosomes"). This must be the largest pathology cemetery ever.

Joshua Sickel: Beautiful case.

Dominic Spagnolo: A very stunning case Michal – thank you. Have never seen this in a humble ovarian fibroma.

James Strauchen: Interesting variant! Is it known what is in the globules?

Saul Suster: Very nice case – haven't seen this before (don't see much GYN pathology). Thank you for sharing this unusual entity with us.

Larry Weiss: Nice case. I had never seen this phenomenon before.

Bruce Wenig: I guess hyaline globules are a recurrent theme for this seminar. Nice case. What do the globules represent?

CASE NO. 15 – CONTRIBUTED BY MARKKU MIETTINEN:

Phil Allen: Sclerosing digital perineurioma, left thumb. I recognized this without any reference to the clinical history or the immunohistochemical findings so I am confident that it is an entity. I am not so sure about the existence of some of the other alleged perineuriomas, excluding of course the tumor formerly known as localized hypertrophic neuropathy. I must congratulate the AFIP soft tissue team, and John Fetsch in particular, for their work on acral tumors.

David Ben-Dor: At least this is a logical explanation for the appearance of meningioma- like lesions outside the central nervous system (more palatable than "ectopic" meningeal tissue).

Gerald Berry: My differential diagnosis included a vascular tumor such as hemangioendothelioma. The immunoprofile supports perineurioma.

Michele Bisceglia: Sclerosing perineurioma. Of the total 4 personal cases I observed 2 were located in the hands, one was in the thigh and another one in the sacral region.

Thomas Colby: Submitted as sclerosing perineurioma. Agree with diagnosis.

Kum Cooper: Thank you, Markku, for sharing this case with us. The ones I see are more often the classic variety with whorls and bipolar cells. I have also had an epithelioid variety (EMA/Glut-1+). The single sclerosing case I had was much more spindled than your case.

Ivan Damjanov: Nice case.

Otto Dietze: Similar to the case we have seen at the USCAP meeting a few years ago.

Hugo Dominguez-Malagon: Nice and illustrative case, totally agree with sclerosing perineurioma.

Göran Elmberger: Thanks for typical and beautiful case. From the perspective of an H&N pathologist recent reports of extra-acral and oral examples of sclerosing perineuriomas are of interest.

Vincenzo Eusebi: Beautiful sclerosing perineurioma.

Giovanni Falconieri: Thank you Markku for this submission. A very didactic case. My pleasure to see you again in Istanbul.

Cyril Fisher: Sclerosing perineurioma with typical cords of cells but elsewhere fibrotic and difficult to diagnose.

Christopher Fletcher: Perfect example of sclerosing perineurioma, just as Markku and colleagues described some years ago. These lesions often seem to be dismissed as 'fibroma NOS'. At least in my experience, recurrence seems to be very infrequent.

Andrew Folpe: Sclerosing perineurioma- nice example.

Jerónimo Forteza Vila: We agree with your diagnosis.

Masaharu Fukunaga: Thank you very much for the beautiful case of sclerosing perineurioma, Markku.

Allen Gown: Nice example of this tumor, and nicely documented, Markku.

Thomas Krausz: Great example.

Janez Lamovec: The second one I see – both seminar cases.

Thomas Mentzel: A wonderful example of epithelioid sclerosing perineurioma.

Michal Michal: Sclerosing perineurioma. Recently I have seen a similar case having, in addition, cytokeratin positive rudimental adenomatous differentiation and mucus inside of the glandular lumina.

Liz Montgomery: Thanks for this lovely example of perineurioma with a lacy look.

Santiago Ramon y Cajal: Thank you, Markku. Sclerosing perineurioma is an unusual entity one should always keep in mind when facing painless nodules in fingers. It's impressive to see how the cuboid cells resemble glomic cells.

Juan Rosai: This is a most peculiar entity. Sclerosing perineurioma is certainly not the first diagnosis that comes to mind to the uninitiated when looking at the H&E sections. However, the evidence that Markku put forward in his articles is very convincing. By the way, some years ago he pointed out to me that figure 25-65 in the 8th edition of the Surgical Pathology Book, supposedly showing a sclerosing glomus tumor, was really an example of sclerosing perineurioma. I quickly took it away from the 9th edition.

Joshua Sichel: Great case, Markku!

Dominic Spagnolo: Nice example of sclerosing epithelioid perineurioma. In the cases we see here, this is an uncommon form; most of ours are "conventional" soft tissue perineuriomas.

James Strauchen: Sclerosing perineurioma. Nice case!

Saul Suster: Thank you Markku for this great example of sclerosing perineurioma. I'm sure I've seen cases like this before but have always missed the diagnosis. This was a valuable education for me!

Larry Weis: Great case—so hypocellular!

Bruce Wenig: It may be the most common form of perineurioma but it is the first sclerosing one I have seen likely related to the fact that the ones I have previously seen were not of the fingers/hands.

Eduardo Zambrano: Great example of sclerosing perineurioma. I must admit that, at first glance, my initial impression was of an epithelioid hemangioendothelioma (the anastomosing cords of epithelioid cells even appear to have lumina, focally), until I recognized the concentric "onion-bulb" arrangement of the lesional cells.

CASE NO. 16 – CONTRIBUTED BY ELVIO G. SILVA:

Phil Allen: Low grade serous carcinoma of the ovary with multiple peritoneal metastases and 10 year survival. I wonder about the prognosis of borderline serous tumors involving the peritoneum and how much they differ from low-grade serous carcinomas of the peritoneum. I also have the greatest difficulty distinguishing peritoneal implants from peritoneal metastases.

David Ben-Dor: I heard Elvio Silva discuss this topic at an update conference Saul organized a few years ago. This topic is somewhat complex, and I'm glad I have the chance to have a glass slide to look at along with his written comments. I used to sign serous tumors out mindlessly as well-moderately-poorly differentiated based on my own 'seat of the pants' understanding, but then I saw Elvio's papers which made some order out of this. The main criterion is nuclear size and pleomorphism- when I first looked at the slide the nuclei were somewhat less monotonous than I expected, with here and there some larger ones approaching what I would think I see in the high grade versions. However this is to some extent an issue of perspective and of relativity, and there aren't any really big weird nuclei often seen in the high grade tumors. In this context micro papillae are associated with a tumor that is "low grade" while in the bladder and the breast, for example, this is associated with "high grade" tumors. However whether a tumor that ineluctably progresses over the years to culminate in death in most instances (though without metastases) can be considered "low grade" is a matter of semantics- maybe a special term should be created for lethal tumors that kill slowly rather than rapidly. Another point I found very interesting and helpful was the fact that low grade serous tumors can have cytoplasmic mucin, which I deduce can result in signet ring cells. About two years ago a patient presented with ascites which showed signet ring cells. Gastroscopy did not reveal tumor and there were no intra-abdominal masses. The gynecological oncologist decided to treat her with an ovarian protocol and she recovered. Afterwards she underwent hysterectomy which revealed a very small carcinoma in the fallopian tube containing signet ring cells. We assume that this was a primary of the fallopian tube with signet ring cell formation- the point Elvio made was very helpful in understanding this.

Gerald Berry: Agree with low-grade serous carcinoma.

Michele Bisceglia: Low-grade serous carcinoma. Thank you very much, Elvio, for the detailed description on the types of invasion by low-grade serous ovarian carcinoma.

Ira Bleiweiss: Agree and great discussion. The micropapillary areas are similar to invasive micropapillary areas of other systems, most notably breast and bladder, but seem not to have the same negative connotations.

Thomas Colby: Submitted as low-grade serous carcinoma. To me this is simply serous carcinoma, perhaps with some focal mucinous differentiation. I am not sure I could (personally) pick this out as a distinct subtype. Thank you for the discussion Elvio; perhaps I am still trainable.

Kum Cooper: Thank you, Elvio, for the in-depth description and discussion. So presumably you do not use the low-grade micropapillary serous carcinoma, non-invasive; which you will call borderline?

Ivan Damjanov: Thanks.

Otto Dietze: Thank you for this excellent presentation of a teaching case.

Hugo Dominguez-Malagon: Low grade serous carcinoma, very illustrative discussion, thank you.

Göran Elmberger: Thanks for bringing this important concept up. Long time ago we always performed ploidy analyses on most epithelial ovarian tumors. I suspect these would show diploid or near diploid stem line features. For unclear reasons we stopped doing this many years ago. Maybe time to start doing p53 and KRAS mutational analyses instead..

Giovanni Falconieri: I wonder how many of such cases I missed. Thanks Elvio, an in-depth and highly educational discussion. It was nice to see you in Istanbul.

Cyril Fisher: Low grade serous carcinoma, many thanks for excellent discussion.

Andrew Folpe: Very nice discussion- thanks.

Jerónimo Forteza Vila: We agree with the diagnosis of low grade metastasis of serous carcinoma of ovarian origin.

Masaharu Fukunaga: Thank you very much for the detailed description of low grade serous carcinoma. Figures 1a and 1b look like micropapillary invasion to me. The term, "invasion" in ovarian tumors is very confusing and the interpretation of "invasion" is different among GYN pathologists and pathologists who do not specialize in GYN pathology.

Allen Gown: Thanks for the interesting discussion about NELS, Elvio.

Thomas Krausz: Elvio, thank you very much for the great discussion. Listening to you in Istanbul, now, I think, I can make the correct interpretation of low grade serous carcinoma.

Janez Lamovec: Thank you for teaching us.

Thomas Mentzel: Many thanks for the nice discussion on this topic.

Markku Miettinen: Serous papillary carcinoma.

Elizabeth Montgomery: Thanks for educating me about low-grade serous carcinoma. I did not realize that these patients had such a protracted clinical course.

Santiago Ramon y Cajal: As you point out, the natural history of low-grade serous carcinoma is indolent and frustrating for patients and clinicians due to the poor response to therapy. Your slides are very good to illustrate the pattern of invasion of these tumors.

Juan Rosai: Very erudite discussion from Elvio Silva. A naïve question: What is the difference between this tumor and Bob Kurman's micropapillary serous carcinoma?

Joshua Sickel: Agree with diagnosis. Thanks for the great discussion.

Dominic Spagnolo: Thanks Elvio for the instructive case and discussion. Unfortunately I don't see much gynae path these days.

James Strauchen: Thank you for the informative discussion. The presence of mucin could be misleading!

Saul Suster: Wow! Thank you for the lucid discussion and for having educated us on this topic. GYN pathologists have managed to turn this field into rocket science and I now find myself utterly intimidated by these tumors.

Larry Weiss: Fabulous discussion.

Bruce Wenig: Thanks, Elvio, for the discussion on invasion in this case.

CASE NO. 17 – CONTRIBUTED BY JAMES STRAUCHEN:

Phil Allen: Erdheim-Chester disease involving the right ventricle. I don't think I would ever have ever diagnosed this one. I suppose the clue is the history of "retroperitoneal fibrosis." Whenever I made a diagnosis of retroperitoneal fibrosis in the past, it always turned out to be something else, usually a sclerosing lymphoma, so I now don't diagnose retroperitoneal fibrosis.

Gerald Berry: Margaret Billingham had a case 20 years ago of cardiac involvement of Erdheim-Chester disease in a patient with a long history of bony disease. A very rare example.

David Ben-Dor: Foamy histiocytes is a rather unremarkable finding on its own – for this case one needs to know the clinical background to make sense of it (or else be very smart and well informed or have had contact with this entity in the past). Do the clinicians have any inkling of this possibility or is the pathologist on his own to make sense of it?

Michele Bisceglia: Chester-Erdheim disease with cardiac involvement. Many many thanks for sharing this case with us. All the sites of involvement by this disease seems now "almost" fully covered after brain and bone (Bisceglia AMR # 26), pulmonary (Colby AMR # 29), and pleural (Suster AMR # Quiz Case in AMR Seminar #35) involvement had previously been illustrated. We just need a case of breast involvement (AJSP April 2010) then we will feel satisfied.

Thomas Colby: Submitted as cardiac involvement by Erdheim-Chester disease. Agree, dense fibrous tissue consistent with ECD. Was there bony involvement or involvement of any other sites? How was the diagnosis of ECD confirmed? I suspect the retroperitoneal fibrosis and hypopituitarism were part of the same process.

Kum Cooper: Wow! Erdheim-Chester disease in the heart! This is certainly a first for me!

Ivan Damjanov: Agree.

Otto Dietze: In my few personal observations of EC-Disease, I have hitherto not seen cardiac involvement, convincing histology.

Hugo Dominguez-Malagon: Intracardial involvement of Erdheim-Chester. Extraordinary case.

Göran Elmberger: Sorry, no foam cells or Touton giant cells present in my levels. Was considering fibroma on blind evaluation. Probably lack of representativeness in my slide. Were long bones involved or other sites sampled?

Vincenzo Eusebi: Spectacular case.

Giovanni Falconieri: Very difficult indeed! I shall look forward to reading Michele's comment since he is an accountable expert on this condition and wrote several papers on the topic. Thank you for submitting this unusual case.

Cyril Fisher: Amazing diagnosis, thanks for the discussion.

Christopher Fletcher: The morphology in this case is entirely convincing. The frequency with which we now recognize this unusual disease in multiple different organ systems seems remarkable, but presumably this simply relates to increased awareness.

Andrew Folpe: What are those peculiar cord-like (?epithelial?) structures? Entrapped mesothelium?

Jerónimo Forteza Vila: Our initial diagnosis was fibromyxoma, but we agree with your diagnosis after a second review. It would be interesting to know if there is a systemic affection or in any other location, in this case.

Masaharu Fukunaga: This is the first time I see Erdheim-Chester disease with cardiac involvement. Thank you very much for sharing this important case. Without history, my impression was Rosai-Dorfman disease. There are some gland- or alveolar-like structures in the slide.

Allen Gown: Thank you for this example, Jim.

Thomas Krausz: I must admit that I did not get the diagnosis until I read your diagnosis and comment. I was too preoccupied with the chronic inflammation and fibrosis and underrated the significance of the histiocytes. I was not aware of the right atrial "tumor" variant of Erdheim-Chester disease before.

Thomas Mentzel: A very rare manifestation of a rare disease.

Michal Michal: I do not think that the lesion is Erdheim-Chester disease. I saw in the slide distinct epithelial cords and nests, which are typical of "Cystic tumor of the atrioventricular node of the heart" (Atrio-ventricular nodal tumor). Interestingly recently this tumor was likened to solid cell nests of thyroid (J.Cameselle-Teijeiro, I.Abdulkader, P.Soaes, N.Alfonsin-Barreiro, J.Moldes-Boullosa, M.Sobrinho-Simoes. Cystic tumor of the atrioventricular node of the heart appears to be the heart equivalent of the solid cell nests ultimobranchial rests of the thyroid. Am J Clin Pathol 2005;123: 369-375)

Markku Miettinen: The available slide is so paucicellular and xanthomatous histiocyte collections so sporadic that it is difficult to connect with histiocytic proliferation/neoplasia such as Erdheim-Chester disease.

Liz Montgomery: Erdheim-Chester disease has such a non-specific appearance that has to be correlated with the clinical distribution and imaging studies. Thanks for this cardiac example – I suspect I would not have thought of the disease and would have performed IgG4!

Santiago Ramon y Cajal: Very difficult case. To tell the truth, since I learned about this entity from cases sent by T. Colby, I am always trying to diagnose it. I wonder the association these cases may have with autoimmunity.

Juan Rosai: Another case of Erdheim-Chester disease! This entity is becoming a strong competitor of Rosai-Dorfman disease, and I don't like it!

Joshua Sichel: I was expecting Rosai-Dorfman disease. Still haven't managed to recognize this enigmatic disease.

Dominic Spagnolo: Erdheim-Chester has become the veritable scarlet pimpernel in pathology. Nice case of cardiac involvement – have never seen it. Thank you.

Saul Suster: Kudos to Dr. Strauchen for making this very esoteric diagnosis on the H&E! Did you have a history available of Erdheim-Chester disease when you reviewed the case? Have imaging studies confirming the diagnosis been done? The name Erdheim is significant to me because the Department of Pathology where I first trained at the Tel-Hashomer Hospital in Israel was named the Erdheim Institute of Pathology in honor of Dr. Erdheim, who's star disciple, Dr. Karplus, immigrated from Vienna to become the first Chairman of Pathology at Tel-Hashomer.

Larry Weiss: I am not convinced this isn't all just reactive.

Bruce Wenig: Looked like a histiocytic-related process (e.g., Rosai-Dorfman-ish) but I did not think of Erdheim-Chester disease. Thanks.

CASE NO. 18 – CONTRIBUTED BY PAUL WAKELY, JR:

Phil Allen: Adult type rhabdomyoma, left shoulder. I think we have had only one of these at Flinders Medical Centre since 1970, and in that adult case, the tumors were multiple. I did see an adult type rhabdomyoma in the buccal mucosa of a child aged about two years which was referred to me by Dr Fan Qin-He from Nanjing about five months ago. It has been previously described in young children.

David Ben-Dor: Thanks for thinking of us in submitting this. It does look obvious after reading the diagnosis, but on first glance the cells looked ground glass to me.

Gerald Berry: Beautiful example of adult type rhabdomyoma.

Michele Bisceglia: Adult type rhabdomyoma. Beautiful case. Have seen 2 such cases in routine practice (one from the neck side and the other one from the basis of the neck - upper sternal region). Clinically both were sent as lymphadenopathies.

Ira Bleiweiss: Agree.

Thomas Colby: Submitted as adult-type rhabdomyoma. Agree with diagnosis.

Kum Cooper: Thank you, Paul. It was good "catching up " with you at USCAP.

Ivan Damjanov: Nice example.

Otto Dietze: I cannot remember having seen a case of rhabdomyoma in the soft tissues outside of larynx and tongue.

Hugo Dominguez-Malagon: Adult rhabdomyoma. Never seen one before at this age, thank you Paul.

Göran Elmberger: Thanks for great case. Lesion is obviously as rare as characteristic.

Vincenzo Eusebi: Adult type rhabdomyoma.

Giovanni Falconieri: Beautiful and didactic example of rhabdomyoma, thanks Paul. My pleasure to get together with you once again in Turkey.

Cyril Fisher: Lovely example of rhabdomyoma, thanks Paul.

Christopher Fletcher: Classic case – thanks.

Andrew Folpe: Great case! These are hard to come by.

Jerónimo Forteza Vila: We agree your diagnosis.

Masaharu Fukunaga: Thank you very much for the beautiful educational case, Paul.

Allen Gown: Nice example of rhabdomyoma.

Thomas Krausz: Very nice example.

Janez Lamovec: Rarely seen lesion.

Thomas Mentzel: Many thanks for sharing this rare lesion!

Markku Miettinen: Adult rhabdomyoma, nice case. I wondered if the shoulder is the right site designation as they are almost always oral/pharyngeal.

Liz Montgomery: Paul, thanks for this. What a lovely rhabdomyoma with spider cells.

Santiago Ramon y Cajal: This is a nice case of rhabdomyoma.

Juan Rosai: Spectacular case of adult rhabdomyoma and a great example of instant pattern recognition.

Joshua Sickel: Magnificent case...thanks, Paul!

Dominic Spagnolo: Nice rhabdomyoma Paul. Thanks.

James Strauchen: Nice example of rhabdomyoma!

Larry Weiss: Nice case.

Bruce Wenig: Rhabdomyoma.

Eduardo Zambrano: Adult-type rhabdomyoma. Contrary to cardiac rhabdomyomas, which are hamartomatous lesions associated to tuberous sclerosis, extracardiac adult-type rhabdomyomas seem to be true neoplasms, not associated to tuberous sclerosis. I did not have an example of this entity in my files. Thank you, Dr. Wakely!

CASE NO. 19 – CONTRIBUTED BY PAUL WAKELY, JR.:

Phil Allen: Alveolar rhabdomyosarcoma infiltrating voluntary muscle, maxillary region. I can't see any bone in my section. I assume the tumor arose in soft tissues and invaded the adjacent bone. I have no doubt that Riopelle, Theriault, Enterline, Horn, Enzinger and Shiraki would all have accepted this as a classical case, without any ancillary investigations.

David Ben-Dor: It should be obvious to the exotic- location would be fine in a child but at this age? My first off the cuff reaction was lymphoma (though the giant cells would look odd in that context). But immuno to the rescue!!

Gerald Berry: Beautiful example of alveolar RMS.

Michele Bisceglia: Alveolar rhabdomyosarcoma. Excellent case, Paul.

Ira Bleiweiss: Agree. It's rhabdo month.

Thomas Colby: Submitted as alveolar rhabdomyosarcoma of the maxilla. Agree with diagnosis.

Kum Cooper: Thank you (again) Paul. Bruce Wenig covered the differential diagnosis of small blue cell tumors in a lovely review of undifferentiated malignant neoplasms of the sinonasal tract in Arch Pathol May 2009; 133(5):699-712.

Ivan Damjanov: Teaching case.

Otto Dietze: I have never seen this in an adult, histology & immunostains are quite typical for me.

Hugo Dominguez-Malagon: Alveolar rhabdomyosarcoma, agree. Multinucleated cells are sometimes difficult to find, but they are a good marker for the differential diagnosis in difficult cases.

Göran Elmberger: Great case. Beautiful giant cells with rhabdomyoblastic differentiation.

Vincenzo Eusebi: Alveolar rhabdomyosarcoma.

Giovanni Falconieri: What a case! The multinucleated tumor cells are pretty catchy. No memory of having seen this before. Looking forward to the soft tissue guns' opinion.

Cyril Fisher: Alveolar rhabdomyosarcoma with solid areas, nice example.

Christopher Fletcher: In adult patients, the upper aerodigestive tract (particularly the sinuses) seems to be the site of predilection for alveolar rhabdomyosarcoma – indeed this is a very nice example. Many thanks.

Andrew Folpe: Nice ARMS. Allen Gown and I stumbled on a very similar case many years ago while looking at expression of desmin in “esthesioneuroblastomas”.

Jerónimo Forteza Vila: Lesion with a highly suggestive histological pattern. We agree with your diagnosis.

Masaharu Fukunaga: Thank you very much for the beautiful educational case, again, Paul. I experienced pure alveolar rhabdomyosarcoma in the uterine body which was very similar to this case.

Allen Gown: Nice contrast with the pleomorphic rhabdomyosarcoma of case 12.

Thomas Krausz: Great case, especially in a 48-year-old.

Janez Lamovec: A classical example of alveolar rhabdomyosarcoma.

Thomas Mentzel: A very impressive example of this partly solid alveolar rhabdomyosarcoma arising in an adult patient.

Markku Miettinen: Alveolar rhabdomyosarcoma, totally convincing without FISH.

Liz Montgomery: This is a beautiful case. What a treat.

Santiago Ramon y Cajal: The amount of malignant multinucleated differentiating rhabdomyoblasts in this case is remarkable.

Juan Rosai: Very nice case of alveolar rhabdomyosarcoma and another example of instant pattern recognition. (now, not in the past). I have several in old Seminars that were called reticulum cell sarcomas by the authorities of the time.

Joshua Sickel: Another collector's item.

Dominic Spagnolo: Nice example of alveolar rhabdomyosarcoma.

James Strauchen: Nice example of head & neck alveolar rhabdomyosarcoma!

Saul Suster: Nice example of alveolar rhabdo in an age group where you don't expect it.

Larry Weiss: Another nice case.

Bruce Wenig: Strange to me that this neoplasm would be considered as an olfactory neuroblastoma. Great example of alveolar RM, solid type with many multinucleated giant cells.

Eduardo Zambrano: Alveolar rhabdomyosarcoma. Very unusual location and patient's age. In a very recent paper (Williamson et al., Journal of Clinical Oncology, May 2010, 28(13): 2151-8), the authors found that the clinical behavior of alveolar cases without PAX rearrangement were indistinguishable from embryonal cases (i.e. less aggressive), and that it significantly differed from the behavior of fusion-positive alveolar cases, which behaved more aggressively. It seems that, regardless of histology (embryonal vs. alveolar features), the critical factor in risk stratification of RMS is the presence of PAX gene fusions. I guess more studies in the future will either corroborate or disprove these findings.

CASE NO. 20 – CONTRIBUTED BY LAWRENCE WEISS:

Phil Allen: Apparently benign mixed cortical adenoma and composite phaeochromocytoma-ganglioneuroma, right adrenal gland in type I neurofibromatosis. Your mixed tumors are really mixing me up as well, Larry!

David Ben-Dor: Is there any particular connection between this lesion and the patient's background condition? The slide is indeed very interesting.

Gerald Berry: Agree. This is the first example of all 3 components that I have seen. Thanks Larry.

Michele Bisceglia: Fantastic case of mixed cortical adenoma and composite pheochromocytoma-ganglioneuroma. Never seen three components in a single tumor.

Ira Bleiweiss: Wow. Three tumors for the price of one.

Thomas Colby: Submitted as a mixed adrenal cortical adenoma and composite pheochromocytoma-ganglioneuroma. Seems to encompass the elements that are present. Is there also neurofibroma involving nerves and fat around the tumor?

Kum Cooper: Thank you, Larry. I have seen a combination of two but never all three before. The cortical adenoma is somewhat difficult on my slide.

Ivan Damjanov: Agree.

Otto Dietze: Fascinating case, I believe that I have found all 3 components.

Hugo Dominguez-Malagon: Interesting combination of the three components as a part of NF-1, thank you for the case.

Göran Elmberger: Thanks. I believe I got all 3 components. Odd lesion.

Vincenzo Eusebi: Mixed cortical adenoma and composite pheochromocytoma-ganglioneuroma. All 3 components present in my slide. Thank you very much.

Giovanni Falconieri: Agree with your interpretation, nice case of mixed adrenal tumor. Never seen the three component in a single glass slide. Thank you for this unusual contribution.

Christopher Fletcher: What a crazy case! It's unfortunate that we have no idea whether this type of admixture reflects 'origin' from adrenal progenitor cells or, instead, simply reflects transdifferentiation between closely related cell types (in the context of embryogenesis). This is the kind of topic that can provoke hours of ultimately inconclusive discussion!

Andrew Folpe: Very interesting case. I'm not sure I see ganglion cells in my section, but everything else is there. Do all of these patients have NF-1?

Jerónimo Forteza Vila: Indeed, the tumor shows a basic component, which reminds us of the two entities mentioned. An interesting case, we agree with the diagnosis.

Masaharu Fukunaga: What a fascinating case! It contains three components. Thank you very much.

Allen Gown: Great case, Larry.

Thomas Krausz: Amazing combination. I am wondering whether the various elements are the same clone or not.

Janez Lamovec: In my slide there are elements of cortical, pheo, and schwannian components admixed with just one focus of ganglion cells – phenomenal case!

Thomas Mentzel: I've never seen this combination before, many thanks !

Markku Miettinen: Pheochromocytoma is definitely there, but it is more difficult to be sure of ganglioneuroma or cortical tumor based on this one slide. One could also consider hyperplastic/intermingling non-neoplastic components. Schwannian medullary proliferation is present, but no ganglion cells there (one focus with normal ganglion cells). Could be early evolution of a small pheochromocytoma in an NF1 patient.

Liz Montgomery: Thanks so much for this adrenal smorgasbord.

Santiago Ramon y Cajal: Beautiful slide for the teaching set!!! I agree with the several components of the lesion.

Juan Rosai: Another spectacular case. It looks like all components of the adrenal cortex and medulla are represented in a very disorganized way, which would seem to fit the criteria of a hamartoma.

Joshua Sichel: This is definitely a first. Another one for the teaching files.

Dominic Spagnolo: Spectacular case of composite adrenocortical adenoma and mixed pheochromocytoma/ganglioneuroma.

James Strauchen: Fascinating combined cortico-medullary adrenal tumor. Thank you!

Bruce Wenig: Great case and one I have only read about and never seen. Thanks.

CASE NO. 21 – CONTRIBUTED BY BRUCE M. WENIG:

Phil Allen: Incompletely excised invasive paraganglioma right carotid body. I have had hardly any experience with these tumors but I would accept this as an invasive paraganglioma. I don't know if it will metastasize. The concentric calcifications which are so prominent in this case are not mentioned in the carotid body section of the fourth series AFIP fascicle.

David Ben-Dor: The contour rather than being smooth is very irregular with tumor reaching the ink on the surface so obviously the tumor couldn't be resected neatly. The relevant newly issued AFIP fascicle states that in "an early study" 50% of carotid body paragangliomas were considered malignant based on capsular invasion and other features. Obviously this is too high a figure so some capsular invasion is probably not significant. However it goes on to say that "aggressive local growth, encirclement of carotid vessels, incorporation of nerves, or invasion near the base of the skull also suggests malignancy, although definitive evidence is provided by metastases". Personally I think that judgments of benignity and malignancy are like any other attempt at predicting the future- they imply some degree of presumptiveness on our part. As the bible says, "prophecy is given to fools" (or something to that effect). What are those prominent ringed pink corpuscles?

Gerald Berry: I don't think any of the current classifications provide a satisfactory scheme for this type of invasive lesions. I think the diagnosis of invasive paraganglioma is useful in that it provides some warning about the biological behavior such as local recurrence.

Michele Bisceglia: Agree on calling your case an invasive carotid paraganglioma. Once had the opportunity to observe a case with venous invasion, which we called only "invasive" complying with the authorities you mentioned. Am not aware that case gave rise to metastatic disease.

Ira Bleiweiss: Paraganglioma, particularly after one knows the location. I would not call it flat out malignant until it metastasizes.

Thomas Colby: Submitted as invasive paraganglioma, incompletely excised. This certainly looks more histologically aggressive than the average carotid body tumor. Has gorgeous pink blobs and evidence of prior ablation with what appears to be embolic material. I think sign out of this case in part depends on one's philosophy. Since this both histologically and grossly at the time of surgery was invasive, I would have no problem calling it invasive paraganglioma (somewhat analogous to the similar situation with thymomas) and that would convey an aggressive biologic potential and I could avoid use of the term malignant paraganglioma because (I seem to recall) metastases would be needed for such a designation.

Kum Cooper: Sclerosing paraganglioma. The two cases I have seen with this morphology had multiple paragangliomas (which may be associated with a familial history-not present in your patient). Some members of our group wrote about these sclerosing paraganglioma not so long ago: Am J Surg Pathol. 2006 Jan;30(1):7-12.

Ivan Damjanov: Chemodectoma. Was it the location or the biology of the tumor that made it unresectable? I did not see anaplasia and thus thought that it was the anatomy rather than the biology that made it so bad.

Otto Dietze: Invasive paraganglioma seems to me the best diagnosis and I would hesitate to call it malignant. Most probably I (or the surgeons) would ask for a second opinion.

Hugo Dominguez-Malagon: Agree with diagnosis of invasive Paraganglioma, I would not classify it as malignant. The presence of abundant psammoma bodies is striking.

Göran Elmberger: Thanks for bringing up difficult topic. In my opinion this lesion does not show any recognized atypical features other than the obvious local "infiltrative" growth. Given the intimate physiological-microanatomical close relationship between the carotid body organ, various nerves and vessels interpretation of "perineural" growth has to be somewhat restricted. I doubt this kind of encasement should be equated with the perineural growth we are seeing in squamous cell carcinomas or adenoid cystic carcinomas in the head and neck. Whether the "infiltrative" nature of the lesion is due to a true inherent biological aggressiveness or merely to advanced local growth secondary to long tumor history remains to be investigated... Do we have same kind of data regarding lesional biology as we have in thymomas or thyroid follicular tumors regarding significance of invasiveness? (Sorry didn't read the cited Shamblin paper) Peculiar looking material used for embolization??

Vincenzo Eusebi: I think that invasive paraganglioma is correct from a practical point of view. Very difficult to predict the behaviour of these tumours.

Giovanni Falconieri: Quite a case, Bruce. I looked at the case without reading the history and come up to the conclusion that this is invasive paraganglioma, and I do not see reasons why we should call it differently. Whether it is benign or malignant is a different story. Histologic criteria of malignancy are disputable in PG. Absent distant metastases, the appellation of malignant is unwarranted, yet I never call these lesions benign. Even local lymph node involvement may be felt as lesion multicentricity rather than metastases (see the extraordinary case of duodenal gangliocytic PG submitted some years ago by Andrew Folpe, AMR50-7). I feel that only long term follow-up may dispel matter.

Cyril Fisher: Invasive paraganglioma, potentially recurrent, metastatic potential unknown.

Christopher Fletcher: Although I have not personally used the term 'invasive' paraganglioma, this does seem a very reasonable way to describe hard-to-resect examples such as this.

Andrew Folpe: Agree with invasive paraganglioma.

Jerónimo Forteza Vila: A typical case with suggestive clinical course and histology. We agree with your diagnosis.

Masaharu Fukunaga: A beautiful case! Thank you very much, Bruce. I agree with you. "Invasive" paraganglioma is new to me. I am very happy to know the classification of paraganglioma, here. It is very simple. I have been wondering what is histologic criteria of malignant paraganglioma.

Allen Gown: Thanks, Bruce. I think this may be one of those tumors that gets defined, ultimately and retrospectively, by its behavior and not by histologic criteria.

Thomas Krausz: Amazing combination. I am wondering whether the various elements are the same clone or not.

Janez Lamovec: We've seen a number of paraganglioma cases in different locations but never a case like this. Therefore, I have nothing constructive to suggest.

Thomas Mentzel: I do agree that infiltrating paraganglioma would be the best diagnosis. However, in my slide at least focally, prominent nuclear atypia with the presence of enlarged hyperchromatic or vesicular nuclei was seen, but I'm not sure about the prognostic importance of this degree of cytological atypia.

Markku Miettinen: Carotid body paraganglioma. Cannot find evidence for malignancy. Nuclear atypia is present and tumor extends into inked margins. This must have some new embolization material that looks like psammoma bodies.

Liz Montgomery: This is a really interesting paraganglioma. Your using the term "invasive paraganglioma" conveys the issues very well. As you point out, it is impossible to diagnose it as malignant.

Santiago Ramon y Cajal: I would favor invasive paraganglioma.

Juan Rosai: Very nice case of sclerosing paraganglioma (our dear old carotid body tumor). In my experience, paragangliomas of the aortic body have a greater tendency to become sclerosed but I have seen similar features in carotid and jugular body tumors. Regarding the terminology, I would call a tumor like this one invasive rather than malignant. After all, we do not use the term malignant for the pheochromocytoma (the king of paragangliomas) of the adrenal gland unless it is associated with metastases, so perhaps we should be consistent and have a similar approach for paragangliomas in other sites. By the way, here are some striking round structures within the tumor that do not seem human. Was something injected into the tumor to shrink it before surgery?

Joshua SICKEL: Agree with diagnosis of invasive paraganglioma...looks locally aggressive. The eosinophilic concretions are quite striking.

Dominic Spagnolo: Invasive paraganglioma seems an appropriate designation for this type of tumour given the intraoperative and gross features of the lesion, and in the absence of overt histological features of malignancy, though as you say, there are no hard and fast criteria for calling a paraganglioma malignant in the absence of metastases. This case has all the features of sclerosing paraganglioma described by several members of the club some years ago (AJSP 2006; 30:7-12), though my impression is that your case is more locally infiltrative than the reported cases. We call bland thymomas invasive, so why not paragangliomas?? This whole area of endocrine path continues to be a murky one.

James Strauchen: Invasive paraganglioma. Bruce, what are the lamellar concretions?

Saul Suster: Very nice example of sclerosing paraganglioma, similar to the cases we reported previously (Am J Surg Pathol 30:7-12, 2006). I think the qualifier "invasive" is appropriate in this context, to alert the clinician to this circumstance. Prediction of biologic behavior or distinction between benign/malignant is an elusive and frustrating exercise in these tumors.

Larry Weiss: I think that "invasive paraganglioma" is appropriate.

Eduardo Zambrano: The proposed classification ("conventional" non-invasive vs. invasive vs. malignant/metastatic) makes sense to me. Based on that, and the clinical information provided, I would have classified this tumor as invasive paraganglioma. I think I would have been in a bind as how to classify this invasive tumor if the degree of pleomorphism, mitotic activity and proliferation rate had been higher, even in the absence of metastatic disease. A long note would have followed my diagnostic header.

CASE NO. 22 – CONTRIBUTED BY EDUARDO ZAMBRANO:

Phil Allen: Recurrent ossifying fibromyxoid tumor, orbital soft tissues. I would not be too worried by the wavering immunohistochemical results. The main thing is to ensure that their unreliability does not infect the pathologist.

David Ben-Dor: I hope it's benign. Any chance of a neurofibroma?

Gerald Berry: Your descriptive classification seems adequate to me.

Michele Bisceglia: In my opinion this tumor is consistent with ossifying fibromyxoid tumor. Recurrent tumor can modify their immunoprofile. CD99 was recently reported as positive in 2 other cases (Miliaras D,

Meditskou S, Ketikidou M. Ossifying fibromyxoid tumor may express CD56 and CD99: a case report. *Int J Surg Pathol.* 2007;15:437-40; Squillaci S, Tallarigo F, Cazzaniga R, Capitanio A. Ossifying fibromyxoid tumor with atypical histological features: a case report. *Pathologica.* 2009;101:248-52)

Ira Bleiweiss: I would have called this OFMT.

Thomas Colby: Submitted as unusual spindle cell lesion with extensively hyalinized stroma. That's sounds good to me but perhaps the soft tissue contingent will come up with something.

Kum Cooper: Looked good for OFMT to me.

Ivan Damjanov: I do not know what this is.

Otto Dietze: I cannot offer another diagnosis. I hope that the soft tissue experts are more helpful.

Hugo Dominguez-Malagon: Hyalinized ossifying fibromyxoid tumor is the best I can think.

Göran Elmberger: Very peculiar look with giant perivascular collagenous pseudorosettes. SFT? Neurilemmoma variant? Meningioma variant? Sclerosing perineurioma variant?

Vincenzo Eusebi: I think it is a benign (myofibroblastic) proliferation. No specific name.

Giovanni Falconieri: Pretty difficult lesion, Eduardo. Cannot say more, sorry. Welcome to the club! It was great to see you in Turkey.

Cyril Fisher: Recurrent OFMT?

Christopher Fletcher: At least in areas, the cytomorphology of the spindle cell component as well as its trabecular arrangement would at least suggest to me the possibility of myoepithelial differentiation – it would be interesting to know whether the recurrence stained for GFAP and whether other keratin stains were also tried. Certainly this is a very unusual case.

Andrew Folpe: This could be a recurrent ossifying fibromyxoid tumor. It would be helpful to verify the primary tumor, of course. CD99 shows up in a lot of places, and I doubt that it has any special meaning here.

Jerónimo Forteza Vila: Sorry we can't offer any new information. Our diagnosis was descriptive, we concur with yours.

Masaharu Fukunaga: Welcome, Dr. Zambrano. The case is very unique and interesting. Despite S-100 protein negativity, it could be ossifying fibromyxoid tumor.

Allen Gown: Not sure what this is, but I don't think that CD99 expression is either unusual or particularly helpful in trying to figure out what this lesion represents.

Thomas Krausz: I still like the original diagnosis of ossifying fibromyxoid tumor despite the different immunoprofile in the recurrent lesion. I am not sure what to do with the immunoreactivity for CD99 but this marker can be positive in various other entities, so I would not change the diagnosis just because of this result.

Janez Lamovec: Plexiform hyalinizing spindle cell (?fibroblastic) tumor with focal ossification, ? unusual OFMT? I don't know how strongly one should rely on immuno results.

Thomas Mentzel: In the differential diagnosis I would like to include a myoepithelioma of soft tissues.

Markku Miettinen: Ossifying fibroma variant, a bone tumor (most likely). Radiologic correlation would be important.

Liz Montgomery: Hmmm. Looks like a low-grade lesion – ossifying fibromyxoid tumor is as good a diagnosis as any despite the odd architecture.

Santiago Ramon y Cajal: The IHC findings of the recurrence are confusing and don't quite fit with anything, therefore I agree with you that a descriptive diagnosis is warranted in this case; however I still think that we may be seeing here an ossifying fibromyxoid tumor or a mesenchymal tumor with a prominent myoepitheliomatous component.

Juan Rosai: I would buy it for an ossifying fibromyxoid tumor of soft parts.

Joshua SICKEL: Favored OFMT on H+E alone. Defer to the soft tissue tumor experts.

Dominic Spagnolo: I see no reason on the basis of this slide to change the original diagnosis of ossifying fibromyxoid tumour. There are no overtly malignant histological features (I found 2 mitoses in the entire section). The lack of S100 positivity in the recurrence does not bother me. Thanks for the case and welcome to the club!

James Strauchen: I don't know but the pattern is very distinctive!

Saul Suster: This tumor shows a very peculiar pattern of fibrosis that I have never seen before in OFMT, not to mention the fact that the cells are spindled and devoid of cytoplasm. Could this be a completely different, new entity in soft tissue tumors? Whatever it is, it's behaving as a low-grade malignancy. If anyone comes across another case like this, could you let us know?

Larry Weiss: My bet is still on ossifying fibromyxoid tumor.

Bruce Wenig: I like the diagnosis of ossifying fibromyxoid tumor (OFT); light microscopic and IHC (1st set) support that diagnosis even if the IHC staining (2nd time around) is not confirmatory. CD99 has been reported in OFT (see - Pathologica 2009;101:248-52 and Int J Surg Pathol 2007;15:437-40.)

CASE NO. 23 – CONTRIBUTED BY HUGO DOMINGUEZ-MALAGON:

Phil Allen: ?Myxoid neurothekeoma, subcutis, right forearm. My section is very poorly preserved and I could not absolutely exclude some other myxoid tumor. To me, this does not look like a plexiform fibrohistiocytic tumor. I could not find Juan Rosai's article in AJSP, February, 2009.

David Ben-Dor: I think that Tom Krausz submitted a similar case to the previous seminar which looked equally as weird. Are there signet ring cells?

Gerald Berry: Agree. Nice example.

Michele Bisceglia: Plexiform fibrohistiocytic tumor / cellular neurothekeoma. Thank you, Hugo.

Thomas Colby: Submitted as plexiform fibrohistiocytic tumor/cellular neurothekeoma. Agree with diagnosis.

Kum Cooper: Having ruled out dermal nerve sheath myxoma; cellular neurothekeoma would be my next port of call: ?NK1-C3.

Ivan Damjanov: I called them neurothekeomas, but PFT sounds good as well.

Otto Dietze: I believe that the clinical presentation and histology is rather typical for this tumor.

Göran Elmberger: Sorry my experience of this type of tumor is very limited. Plexiform growth is difficult to see in a small biopsy. Myxoid lesion partly favours NTK mixed but IHC seems to be more indicative of fibrohistiocytic lineage – cellular NTK?

Vincenzo Eusebi: I leave the comment on this case to Dr. Rosai. Personally before signing out a definitive diagnosis on this case I would ask for the entire excision of the lesion.

Giovanni Falconieri: Hugo, I found this very challenging and out of my interpretive possibility. Thanks for this uncommon case contribution and for the discussion. Good to see you in Istanbul, Hugo.

Cyril Fisher: Cellular neurothekeoma since plexiform fibrohistiocytic tumor is less commonly myxoid.

Christopher Fletcher: At least to me, the appearances of this cytologically atypical myxoid spindle cell neoplasm are quite different from both cellular neurothekeoma and plexiform fibrohistiocytic tumour and, at least on H&E, I find this lesion very difficult to classify. In my personal opinion, I believe that plexiform fibrohistiocytic tumour and cellular neurothekeoma are quite different morphologically. In particular, one does not see the long spindle cell fascicles of plexiform FH in cellular neurothekeomas and, conversely, cellular neurothekeomas only rarely extend into underlying subcutis. Nevertheless, I am aware that this is a controversial issue.

Andrew Folpe: Cellular neurothekeoma with myxoid change. I'm not convinced that PFHT and CNTK are the same tumor, although I think some have been misdiagnosed as the other over the years.

Jerónimo Forteza Vila: We agree with your diagnosis. It is the first case we received of this entity.

Masaharu Fukunaga: It is a very difficult case. Thank you very much, Hugo. I did not imagine plexiform fibrohistiocytic tumor/cellular neurothekeoma.

Thomas Krausz: Cellular neurothekeoma is the most likely. It looks different than the plexiform fibrohistiocytic tumors I have seen before. However, I will read Dr. Rosai's paper more carefully to understand the suggested relationship of these entities.

Janez Lamovec: Nice case, Hugo. I wouldn't add anything to your interpretation.

Thomas Mentzel: I do agree with the diagnosis of a somewhat of plexiform or multinodular myxoid lesion, and I think that the lesion represents a myxoid cellular neurothekeoma. Did neoplastic cells stain positively for NK13? However, I believe that cellular neurothekeoma and plexiform fibrohistiocytic tumour are two different entities with different clinicopathological features, and I hope that we will better define the true line of cellular neurothekeoma in the near future!

Michal Michal: Plexiform fibrohistiocytic tumor. It is amazing how many "faces" this tumor can have.

Markku Miettinen: Myxoid neurothekeoma (non-nerve sheath tumor) is agreeable, considering immunohistochemical findings. Other markers that would have been of interest include microphthalmia transcription factor, C10, and CD63. All are positive in neurothekeoma although none has exclusive specificity. In some cases, including this, distinction from myxoid nerve sheath tumors can be difficult (in this case myxoid neurofibroma with epithelioid component).

Liz Montgomery: This looks like my concept of cellular neurothekeoma, recognizing the overlap/spectrum with plexiform fibrohistiocytic tumor – although the classic plexiform fibrohistiocytic tumor has giant cells and looks similar to fibrous histiocytoma (except that it is plexiform) and not like this lesion. Older literature was very confusing vis a vis about what we now call "nerve sheath myxoma" versus "cellular neurothekeoma" but the papers by Markku and Chris have nicely separated the two and presumably Markku, Chris, and Juan will have further comments:

1: Fetsch JF, Laskin WB, Miettinen M. Nerve sheath myxoma: a clinicopathologic and immunohistochemical analysis of 57 morphologically distinctive, S-100 protein- and GFAP-positive, myxoid peripheral nerve sheath tumors with a predilection for the extremities and a high local recurrence rate. *Am J Surg Pathol.* 2005 Dec;29(12):1615-24.

2: Fetsch JF, Laskin WB, Hallman JR, Lupton GP, Miettinen M. Neurothekeoma: an analysis of 178 tumors with detailed immunohistochemical data and long-term patient follow-up information. *Am J Surg Pathol.* 2007 Jul;31(7):1103-14.

3: Hornick JL, Fletcher CD. Cellular neurothekeoma: detailed characterization in a series of 133 cases. *Am J Surg Pathol.* 2007 Mar;31(3):329-40.

Santiago Ramon y Cajal: Nice case. Thank you!

Juan Rosai: Nice case of neurothekeoma. It is cellular and myxoid at the same time. I would like to thank Dr Malagon who having quoted our paper suggesting a possible relationship between this tumor and plexiform fibrohistiocytic tumor. I already hear rumbling from other members of the club.

Joshua Sichel: Agree with diagnosis of neurothekeoma with atypical features (benign). Recently saw a case of cellular neurothekeoma at a South Bay pathology meeting which was more cellular, lacked the

myxoid stroma features and was mitotically active. I thought it was amelanotic melanoma, but the IPOX markers were negative.

Dominic Spagnolo: On this section I could not be sure this is not a small and superficial form of myxoid MFH (high grade myxofibrosarcoma). There are even atypical mitoses in my section, the degree of pleomorphism I find worrying, and one of the two fragments has a diffuse pattern of growth. The immunophenotype does not allow distinction either.

James Strauchen: I also considered a myxoinflammatory fibroblastic tumor.

Larry Weiss: My preference is "plexiform myxoid tumor".

Bruce Wenig: Given the demographics, subcutaneous location, histology including lobularity, vague septated architecture, prominent myxoid stroma and round to spindle shaped cells, looks like a classic (rather than cellular) neurothekeoma; not sure the absence of S100 protein excludes that diagnosis. The findings in the slide I received do not quite look like a PFT or cellular neurothekeoma to me.

Eduardo Zambrano: On H&E I, would have interpreted this as a myxoid neurothekeoma, but given the absence of S100 protein expression, I would have favored a diagnosis of cellular neurothekeoma. I am looking forward to further comments by Dr. Rosai in relation to a histogenetic link of these tumors with plexiform fibrohistiocytic tumor.

CASE NO. 24 – CONTRIBUTED BY HUGO DOMINGUEZ-MALAGON:

Phil Allen: Whorled tumor resembling a meningioma, which in my section is histologically bland, in neurofibromatosis, left interscapular region. I don't think my section can be adequately representative because I have no necrosis and hardly any mitoses. On the basis of all the information, I guess it is a malignant tumor of peripheral nerve with an unusual meningioma-like pattern.

David Ben-Dor: I understand your dilemma. Maybe it would have been better not to do immuno but to sign the case out on the basis of morphology as in the dark ages?

Gerald Berry: With the diagnosis of NF I would have headed down the MPNST direction!

Michele Bisceglia: Very difficult differential diagnosis based on morphology and immunohistochemistry alone (given the clinical context of NF1). EM may help in this case. I personally favour SFT (dedifferentiated).

Ira Bleiweiss: ?? - No clue.

Thomas Colby: Submitted as ? dedifferentiated SFT, dedifferentiated peripheral nerve sheath tumor (perineurioma)? I am not sure I can put this case together given the histology and the immunophenotype but I have to think that the history of NF is significant and that this directly or indirectly is related to that and is a close cousin of a peripheral nerve sheath tumor that looks more like a perineurioma. Tumors like this justify the existence of a club like the AMR club.

Kum Cooper: Perineurioma can be CD34+. EMA can be very weak and focal. How about Glut-1 and claudin-1?

Ivan Damjanov: I think that this tumor cannot be properly classified, but to me it is most compatible with a PNST (especially in a patient with neurofibromatosis).

Otto Dietze: Malignant SFT would be my first choice.

Göran Elmberger: I have respect for strange tumors occurring in setting of NF. Do we know if NF1 or 2? My first impression on blind review was meningioma. Maybe some relationship with perineurioma... IHC in atypical or dedifferentiating tumors can be aberrant. After all I also favour dedifferentiated peripheral nerve sheath tumor (perineurioma variant?) even if similarity to meningioma is great. Metastasizing atypical meningioma??

Vincenzo Eusebi: It is fine with me to regard the present tumour as belonging to the group of HPC/SFT. The lesion does not look so aggressive to me in the slide you sent. It is fine to call the lesion dedifferentiated SFT taking in account the areas of high grade spindle cell sarcoma you did not send to us. I am looking for Chris Fletcher's comments.

Giovanni Falconieri: Difficult case. However I am more inclined to consider PNST rather than SFT; for SFT morphology (and immuno as well) do not fit very well as long as most SFT are CD99+.

Cyril Fisher: In this situation I suggest MPNST; EM can sometimes help here!

Christopher Fletcher: Given the history of NF-1 and the very organoid appearance of the whorled structures in these slides, combined with the fact that you described high-grade sarcomatous features elsewhere, then it would seem to me most likely that this represents a high-grade MPNST. Since less than 50% of MPNSTs stain for either S-100 or GFAP then it is often difficult to prove the latter diagnosis by immunohistochemistry – but it is worth noting that CD34 is commonly positive in MPNST.

Andrew Folpe: I'd be shocked if this wasn't perineurial. If you want to send us slides, we will do GLUT-1 and claudin-1 for you.

Jerónimo Forteza Vila: The lesion shows resemblance, in some areas, with a meningioma; although the immunohistochemistry profile does not coincide. We accept your diagnosis as a possibility.

Masaharu Fukunaga: It looks like perineurioma despite EMA negativity. It could be dedifferentiated peripheral nerve sheath tumor with perineurioma-like features. I will be interested in EM. Thank you for another fascinating case, Hugo.

Allen Gown: I vote for malignant peripheral nerve sheath tumor; but would like to know what was the Ki67-defined cell proliferation rate?

Thomas Krausz: Diagnostically challenging case. Without EMA immunoreactivity I cannot diagnose perineurioma, even though the morphologic resemblance is close. Dedifferentiated SFT is the most likely provided there is no adjacent WD liposarcoma in further tumor sampling (if there is, then dedifferentiated liposarcoma).

Janez Lamovec: I would rather call this PNST than SFT, immuno notwithstanding. I wonder what the opinion of experts will be.

Thomas Mentzel: Given the morphological features and reported immunohistochemical stainings as well as the presence of a sarcomatous component, I would favour the diagnosis of dedifferentiated solitary fibrous tumour showing focally perineurioma-like features.

Michal Michal: Solitary fibrous tumor with whorls like those occasionally seen in liposarcomas. Nice case.

Markku Miettinen: Puzzling case. Pacinian corpuscle-like elements, but after all might be solitary fibrous tumor variant (CD34+ variably). I could not find high mitotic activity, although malignant potential cannot be ruled out based on large size and overall features. This case again shows that NF1 patients can have any tumors other than nerve sheath tumors.

Liz Montgomery: Looks like a solitary fibrous tumor with meningotheial-like whorls to me on the provided slide. The high-grade component you describe will of course drive the outcome.

Santiago Ramon y Cajal: I would favor a malignant peripheral nerve sheath tumor. The different morphologic patterns of the neoplasm are quite interesting, specially the areas with striking whirly configuration (meningioma like).

Juan Rosai: This tumor has to be of a peripheral nerve sheath type considering the striking neuroid whorls, the storiform pattern, and the fact that the patient has neurofibromatosis. As for the specific type, I think it is probably a low grade malignant peripheral nerve tumor (a sort of malignant neurofibroma).

Joshua Sickel: Strange case. I considered an unusual de-differentiated liposarcoma with meningotheial/neural-like whorling growth pattern (Am J Surg Pathol. 1998 Aug;22(8):945-55). Given the clinical history, I would do my best to exclude MPNST. Anxious to hear from the soft tissue guru's.

Dominic Spagnolo: Irrespective of the immuno findings, I think this is a malignant peripheral nerve sheath tumour with heterogenous cytoarchitecture and "onion bulb" formations akin to those found in localized hypertrophic neuropathy. Given that there is clear cut dedifferentiation in other areas of this large tumour, the features in this slide are of a lower grade, paucimitotic area. There is an attenuated nerve splayed over the capsule of the lesion. There are hemangiopericytoma-like areas and storiform areas resembling storiform perineurioma. A good proportion of the onion bulbs appear to have central axons, particularly in the subcapsular aspect of the tumor; a neurofilament stain would be interesting. Such formations are rarely described in neurofibroma and schwannoma. They are often referred to as curlicue arrangements in MPNST, but whether any of these might include true onion bulbs with central axons, or pseudo-onion bulbs of the type found in intraneural perineurioma, I don't know. I have a typical Schwannoma showing this phenomenon sitting on my desk for the last 2 years, waiting for a companion to show up. A spectacular case – thanks.

James Strauchen: Pacinian neurofibroma/MPNST.

Saul Suster: I have seen a couple of cases with meningothelial-like whorls in otherwise classical solitary fibrous tumors. These whorls are non-specific and may be seen in many unrelated types of tumors, such as meningioma, perineurioma, dedifferentiated liposarcoma and spindle cell thymoma. The presence of a hemangiopericytic component would be unusual (at least for me) for a PNST. Also, neurofibromatosis unfortunately does not confer its patients with protection from developing other tumors besides neural neoplasms. Having said this, common things are more common and logic would indicate that this tumor is likely to be of neural origin. If it is, this would be a very unusual morphology for a MPNST. Immunohistochemistry has not been very helpful in this case so far, I'm wondering Hugo if you have any wet tissue left for E.M. because that could potentially contribute to solve the issue here.

Larry Weiss: I think that malignant peripheral nerve sheath tumors can do anything they want at times, especially in the setting of neurofibromatosis. I would not get too caught up in the components.

Bruce Wenig: Looks more perineurioma-like than peripheral nerve sheath or SFT, but given the IHC staining perhaps an unusual variant of SFT, but one that I have not encountered previously.

Eduardo Zambrano: Tough case. I sympathize with Hugo. Given the clinical history of NF1, and the presence of a large tumor with areas of a high grade spindle cell sarcoma, I would favor perineuriomatous dedifferentiation in an MPNST. I am not sure what to do with the EMA negativity and CD34 positivity, but perhaps immunostains for Glut-1 and claudin would help.

CASE NO. 25 – CONTRIBUTED BY SAUL SUSTER:

Phil Allen: Undiagnosed, histologically benign, myxoid tumour with inflammatory cells and vague chondroid appearance, wall of the distal end of the right ureter. I would suggest adding myxoid inflammatory myofibroblastic tumor to the list, but it does not fit very well. Perhaps it has forgotten how to stain with SMA and has also assumed an S100 negative chondroid appearance. The inflammatory cells are certainly very prominent. It looks benign to me.

David Ben-Dor: Reactive process n.o.s.? Looks benign histologically.

Gerald Berry: Sorry. I considered the same things as you did in the differential diagnosis and couldn't come up with a definitive diagnosis.

Michele Bisceglia: I do not know what this lesion is. Obviously, if plasma cells are monoclonal (light chain restriction) serum analysis and bone marrow trephine biopsy are requested to ascertain any plasma cell proliferative disease. Plasma cells seems infiltrating an indeterminate myxochondroid soft tissue lesion. Tumor in tumor? In the past I had the opportunity to see a case of chronic lymphocytic leukemia infiltrating a skin recurrence nodule of invasive ductal carcinoma of breast and another time another chronic lymphocytic leukemia infiltrating squamous cell carcinoma of skin. Anyway, I just expressed very improbable events, since in essence I do not know what this case is.

Ira Bleiweiss: I think this is extraskeletal myxoid chondrosarcoma.

Thomas Colby: Submitted as HELP! I would wonder about a peculiar IMT.

Kum Cooper: Saul, did you try IgG4 to rule out lymphoplasmacytic sclerosing disease?

Ivan Damjanov: Myxoid tumor. Did not worry me too much but I have no idea about its histogenesis.

Otto Dietze: Sorry, I can't offer a definite diagnosis; according to your findings I believe that it is a benign process and I wonder whether it might present a reactive condition with peculiar metaplastic changes in the stroma. There is a prominent vascular proliferation on one side of the lesion and I don't believe that it belongs to the normal vascularization in this region. Probably it is the remnant of another structure – like an urethral polyp – which has spontaneously discharged long time ago.

Hugo Dominguez-Malagon: Difficult case. Peripheral nerve sheath tumor?, myoepithelioma?, myxoinflammatory acral fibroblastic tumor?, solitary fibrous tumor?

Göran Elmberger: That's a tough one. Tumor. Mesenchymal. Low-grade? Basically I have no idea. I was considering your differential of extraskeletal myxoid chondrosarcoma with the same contrast as yourself. Still fits with IHC. Maybe I would use some of the remaining slides for translocation analyses aimed at EMCS. Dedifferentiated liposarcoma with whirling (MDM2)?? GIST variant (you avoided CD34?)??? Array cytogenetics?

Vincenzo Eusebi: I do not think it is neoplastic. I would include this lesion in the group of pseudotumors of the kind seen in the bladder. Amyloid deposits should be excluded.

Giovanni Falconieri: I am not sure of what it is. Is there any reactive lesion that can do this? Perhaps a close oncologic monitoring may be revealing. I would like to thank you and Volkan once again for organizing with Dr. Ruacan the last meeting in Istanbul. It was a memorable and rewarding experience.

Christopher Fletcher: This is indeed a very strange-looking lesion and, given Saul's careful work-up, it is difficult to come up with any convincing diagnostic suggestion. Certainly the appearances would not seem to fit with any currently defined entity. In this situation, it is always so very difficult to predict the biologic potential of unclassified lesions such as this.

Andrew Folpe: Might be interesting to look for the extraskeletal myxoid CS fusion in this. We can do this in paraffin, if you'd like to send unstained slides.

Jerónimo Forteza Vila: Discard lesion of inflammatory granulomatosis with plasmatic cells.

Masaharu Fukunaga: It is very challenging. Myoepithelioma, myxoid chondrosarcoma, Rosai-Dorfman disease?

Allen Gown: Still wonder about a vascular neoplasm; would be interesting to run FL1 on this case. Also IN11 to address possibility of epithelioid sarcoma.

Thomas Krausz: I am not sure what this is, but in view that the lesion looks encapsulated together with a dense lymphoplasmacytic infiltrate I would suggest degenerate/ancient schwannoma with myxoid change and reexamine the S-100 to see whether there are a few remaining Schwann cells at the periphery. Perhaps also an EMA to highlight perineurial cells in the possible capsule.

Janez Lamovec: I don't know. ?Some variant of myoepithelial tumor, immuno dead.

Thomas Mentzel: A difficult case indeed! I was thinking on an inflammatory pseudotumor, but I`m not sure !

Michal Michal: ??Strange myxoid chondrosarcoma??

Markku Miettinen: Another puzzling case. Myofibroblastic neoplasm, inflammatory myofibroblastic tumor variant would be a possibility. ALK immunostain would be of interest. GYN-stromal tumor could also be possible, and evaluation of estrogen receptor could be useful.

Liz Montgomery: Saul, where do you find these cases? Other than the crazy inflammation this reminds me most of chondroid lipoma and my hunch is that it is a similar thing and benign but not really sure but

also thought of extraskeletal myxoid chondrosarcoma. I would anticipate that this patient will do well but would have written a carefully worded report!

Santiago Ramon y Cajal: I have no idea of what this diagnosis could be. My impression is that it may be a hamartomatous lesion. I don't see clear features of malignancy.

Juan Rosai: I would suggest a myxoid variant of inflammatory pseudotumor/inflammatory myofibroblastic tumor, but not with great conviction.

Joshua Sickel: Possibly a myxoid variant of inflammatory myofibroblastic tumor? I favor something benign.

Dominic Spagnolo: Not sure Saul, but I favor some weird form of an inflammatory pseudotumor (pseudosarcomatous myofibroblastic proliferation). ?ALK staining maybe.

James Strauchen: Myxoid inflammatory myofibroblastic tumor with numerous plasma cells.

Saul Suster: I want to thank everyone for their comments and suggestions on this case. I still don't know what this is. Since submitting the case, I have received additional clinical information. The patient apparently was seen for flank pain and was found to have hydronephrosis. The surgeon went in to remove the kidney and ran the ureter to identify the source of the obstruction encountering this nodule which was circumferentially growing around the wall of the ureter proximal to the bladder. We have now done an IgG4 and an ALK-1. The ALK-1 was negative and the IgG4 showed a few scattered positive plasma cells. I also ordered the FISH assay for the EWS gene rearrangement to rule out extraskeletal myxoid chondrosarcoma (thank you Andrew for offering to do this at your place). The results of the FISH assay for EWS in our lab was negative. In revisiting this case, it definitely looks more like an inflammatory or reactive process rather than a neoplasm. The chondromyxoid-appearing nodules, however, threw me off because I have never seen anything like this before in an inflammatory or reactive process. I don't understand the reason for the kappa light chain restriction; the patient has no known monoclonal gammopathy or any other manifestation of plasma cell dyscrasia. I guess an unusual form of inflammatory pseudotumor is possible, but it would be strange for the spindle cells in such condition to be negative for SMA. The CD34 positivity is also unusual in this setting. In short, this is a strange case that is still taking away my sleep. If anyone comes across something similar in the future please let me know so we can commiserate.

Larry Weiss: Not sure I understand the kappa/lambda stains. With MIB-1 essentially negative in the spindled cells, any chance it is a plasmacytoma with a funny stromal reaction?

Bruce Wenig: Some of the features struck me as resembling those seen in a chondromyxoid fibroma, a tumor that may rarely occur in soft tissue sites. Other than CMF (although I thought about a parachordoma but light microscopy and IHC do not fit), I do not know what this tumor is but it looks benign.

Eduardo Zambrano: I saw this case at MCW with Dr. Suster and, like him, I don't know what to do with this lesion. I also pledge to the group's help. Thanks to everyone for sharing such interesting cases, and for allowing me into such a distinguished group of colleagues!

FOLLOW-UP COMMENTS TO AMR SEMINAR #56

CASE NO. 17 – CONTRIBUTED BY DOMINIC SPAGNOLO

Follow-up comments by Dominic Spagnolo on Seminar 56, Case 17:

Understandably, this case engendered some polarized views of lymphoma vs reactive. I can provide the latest follow-up. This patient remains completely well, now about 65 months post-splenectomy, during which time she had another uneventful pregnancy to term and normal delivery. There is no indication of lymphoma clinically. The hematologist (a very senior and experienced hematologist) thanks members for their opinions. He stressed that (1) it was patient reluctance that did not lead to earlier splenectomy; (2) the extraordinary history of relapsing and completely remitting massive splenomegaly is strongly against lymphoma in his opinion (and mine). She has not received any treatment.