

## **AMR Seminar #59 – Short Summary of Cases:**

- Case 1:** 75-year-old male with a lesion on the dorsum of right hand.
- Case 2:** 2-year-old boy who presented with an orbital tumor.
- Case 3:** 49-year-old man with 9cm. prostatic tumor.
- Case 4:** 59-year-old man with huge adrenal mass.
- Case 5:** 22-year-old man with longstanding history of a large, 45cm. keloid-like mass in his lower back.
- Case 6:** 74-year-old female with history of breast cancer, now presents with anemia.
- Case 7:** 27-year-old male with worsening headache and left arm numbness and weakness for two days.
- Case 8:** 23-year-old woman with recurrent malignant melanoma of the leg.
- Case 9:** 50-year-old patient underwent hysterectomy and lymph node dissection for endometrial carcinoma.
- Case 10:** 9-year-old male with a slowly progressive growth of the incisor mandibular region.
- Case 11:** 51- year-old lady with a subcutaneous nodule of the left hip.
- Case 12:** 58-year-old female with a history of pANCA-positive vasculitis with an incidental renal mass.
- Case 13:** 78-year-old man with an incidental well-circumscribed 10 cm mass located in the retroperitoneum.
- Case 14:** 62-year-old woman underwent a right knee total arthroplasty for severe degenerative joint disease.
- Case 15:** 49-year-old woman with menometrorrhagia had a total hysterectomy and double annexectomy.
- Case 16:** 46-year-old female, with a history of infiltrating ductal carcinoma of the breast now presents with an enlarging uterine mass measuring 12.5 cm.
- Case 17:** 22-year-old woman with a solitary tumor of the left lung.
- Case 18:** 34-year-old male with tumor measuring 16 mm in size in the parotid gland.
- Case 19:** 5-month-old otherwise healthy baby boy with a polypoid skin nodule in the umbilicus.
- Case 20:** 63-year-old man presented with an enlarging splenic mass and underwent laparoscopic splenectomy.
- Case 21:** 25-year-old man who was seen 5 years ago for evaluation of a large anterior superior mediastinal mass. Now presents with a large adrenal mass.
- Case 22:** 33-year-old white female had resection of a skull base meningioma at the age of 15 years; she has now developed a mass in the infratemporal fossa and temporal bone.
- Case 23:** 62-year-old man with papillary thyroid cancer diagnosed 2 yrs. ago presents with a right renal mass.
- Case 24:** 84-year-old female with an enlarged spleen.
- Quiz Case #1:** 59-year-old male presented with an enlarging sublingual mass.

# AMR SEMINAR #59

## CASE 1

**Contributed by:** Philip Allen, M.D., Flinders Medical Centre, South Australia

**Case Identification:** FMC 10/S06813, Goulburn Valley Health H-104021

**Contributor:** Dr. Terry Schultz, Department of Anatomical Pathology, Goulburn Valley Health, Shepparton, Victoria 3630, Australia.

**History:** 75-year-old male with a lesion on the dorsum of right hand, ?giant cell tumor. The specimen consisted of a smooth surfaced, roughly egg-shaped piece of tissue 35 x 30 x 24 mm with a delicate external capsule. The cut surface had a whorled appearance

**Diagnosis:** Sclerotic (fibroma-like) lipoma, dorsum of right hand.

**Comments:** The histology of this tumor closely matches the description in the article by William Laskin, John Fetsch and two of our club members in Am J Dermatopathol 2006;28:308-316. I only became aware of this entity because of my interest in tumors of the hand, but sclerotic lipoma was first described by Zelger in a series of five cases which included three on the scalp and only two on the hands. However, the AFIP study only retrieved cases from the hands, feet, wrist or ankle so it is possible this tumor also has a predilection for the scalp.

I note that mast cells are a feature which sclerotic lipoma shares with spindle cell lipoma, and the current tumor was CD34 positive. Some of the AFIP tumors were also weakly CD34 positive. The AFIP authors have already raised the possibility of a relationship to spindle cell lipoma. Do any of the panel members, particularly Markku and Michal, have any new information about monosomy or partial loss of chromosomes 13 or 16 in sclerotic lipomas?

# AMR SEMINAR #59

## CASE 2

**Contributed by:** Carlos E. Bacchi, M.D.

**Clinical History** (reference CB 23154/10):

This is a 2-year-old boy who presented with an orbital tumor. A surgery was performed and a 5 x 3.8 x 3.7 cm tumor from the retroocular area was removed.

**Pathology Findings:** The histological sections of this lesion reveal a highly malignant tumor formed mainly by giant bizarre pleomorphic multinucleated cells with hypochromatic nuclei and sometimes with pseudonuclear inclusions. These cells also display multiple prominent eosinophilic nucleoli and abundant, pink, dense cytoplasm. There are areas of geographic necrosis. Many mitotic figures are present including aberrant and multipolar mitosis. Apoptotic bodies as well as hyaline globules in the cytoplasm of some cells are also seen. There are also neoplastic spindle cells with moderate pleomorphism. Immunohistochemistry studies demonstrated expression of desmin and myogenin with negativity for smooth muscle actin, CD34 and S-100 protein (images in the AMR site). There was expression of cytokeratin in a few cells. Desmin was expressed in about 60% of the tumor cells and myogenin in about 30%. Myogenin expression was present both in giant bizarre pleomorphic multinucleated cells and in the spindle cells.

**Diagnosis:** Anaplastic embryonal rhabdomyosarcoma.

**Comments:** The presence of enlarged, atypical cells with hyperchromatic nuclei defines the anaplastic variant of embryonal rhabdomyosarcoma. This feature may be seen in both embryonal and alveolar tumors but is more prevalent in the former. Anaplastic features can be focal or diffuse, like in this case. Kodet et al define anaplasia-pleomorphism in rhabdomyosarcoma as the presence of cells with large lobated nuclei at least three times larger than the common tumor cell population in RMS. Anaplasia in RMS is associated with worse prognosis especially if it is diffuse rather than focal. Still according to Kodet et al, RMS with anaplastic-pleomorphic features is rather uncommon (about 3% of all RMS studied in the Intergroup Rhabdomyosarcoma Study). As transitions from typical nonanaplastic embryonal RMS and alveolar morphology to various grades of anaplasia has been described in the same tumor, it is believed that pleomorphic (anaplastic) rhabdomyosarcoma is not a separate entity in the pediatric age group. The morphological differential diagnosis in this case is quite broad and includes all the sarcomas that may reveal areas of pleomorphism. On the other hand, taking in account the patient's age, the anatomic location (head and neck) and the expression of desmin and myogenin by the tumor cells, the definitive diagnosis is straightforward.

**References:**

1. Kodet E et al. Childhood rhabdomyosarcoma with anaplastic (pleomorphic) features. Am J Surg Pathol 17(5): 443-453, 1993.
2. Parham DM. Pathologic classification of rhabdomyosarcomas and correlations with molecular studies. Mod Pathol 14(5): 506-524, 2001.

# AMR SEMINAR #59

## CASE 3

**Contributed by:** Michele Bisceglia, M.D. (slides labeled 57036-2)

**Clinical History:** In 2002, a 49-year-old male, who had undergone transurethral prostatic resection for benign nodular hyperplasia and left hydrocelectomy 4 and 2 years previously, respectively, was admitted for acute urinary retention. Previous pathological specimens were not available for review. At this time rectal digital examination revealed an enlarged firm prostate gland. Abdominal CT scan and US scan showed a prostatic tumor 9 cm in size with infiltrative margins, bulging into the urinary bladder and invading the perirectal adipose tissue. Bilateral hydronephrosis due to obstruction of both the ureters and enlarged iliac lymph nodes were also documented. At cystoscopy a polypoid tumor obstructing the prostatic urethra was seen and a transurethral tumor resection was performed (slides enclosed).

**Histology:** Light microscopic examination revealed a malignant tumor composed of an admixture of undifferentiated small round cells and scattered groups of spindle-shaped cells with bipolar eosinophilic cytoplasmic extensions showing definite cross striations.

**Immunohistochemistry:** The tumor cells were positive for vimentin, muscle specific actin, desmin, fast myosin, sarcomeric actin, and negative for CD34, EMA, S100 protein, PSA, PSAP; pan-cytokeratin (MN116) was focally positive in a few cells.

**Diagnosis:** Primary embryonal rhabdomyosarcoma of prostate in adult.

**Follow-up:** After several courses of neoadjuvant VAC-chemotherapy (vincristine, adriamycin, and cyclophosphamide), which reduced the tumor mass to 5 cm, the patient underwent radical cystoprostatectomy with bilateral seminal vesiculectomy and pelvic lymphadenectomy. Urinary diversion was accomplished with creation of bilateral ileal conduits. The original diagnosis was histologically confirmed on examination of the resection specimen. The urethral resection margin was positive for tumor. Both seminal vesicles, the iliac lymph nodes, as well as the resection margins of both ureters, were all free of tumor. 6 months after surgery a huge pelvic recurrence of the ERMS, causing intestinal occlusion and bilateral ureteral obstruction which were relieved with percutaneous nephrostomy and transverse colostomy, was found and confirmed on needle biopsy. The patient became cachectic and severely debilitated and died 1 year after diagnosis. Distant metastases were not documented. Autopsy was not done.

**Discussion:** Embryonal rhabdomyosarcoma (ERMS) is the most common tumor of the lower genitourinary tract occurring in the first 2 decades of life, both in males and females, mostly arising from the bladder, vagina, uterine cervix, prostate, and paratesticular region. ERMS of prostate in adults is extremely rare, accounting for less than 5% of all malignant prostatic tumors. ERMS is the rarest type of sarcoma in this age group. In a systematic review, which was published by Waring et al in 1992, only 6 cases were found in the literature with adequate clinicopathological information, to which these authors added 3 cases of their own.<sup>1</sup> Occasional case reports of ERMS in adults were published since. I personally reviewed the literature on this subject, encompassing the interval between 1988 (the year when Waring's et al<sup>1</sup> review ended) and May 2010. Around 40 cases of primary prostatic rhabdomyosarcoma have been reported so far in males  $\geq 18$  years of age from 1988 to May 2010. However, in compliance with Waring's et al inclusion/exclusion criteria,<sup>1</sup> less than 30 cases should be included, which, in addition to the cases recorded in the afore-mentioned review, amount to a grand total of less than 40. ERMS mostly present with symptoms of progressive dysuria or urinary obstruction. Patients often present with locally advanced disease and at times with metastatic disease. A tumor mass is always discovered and the diagnosis is made on transrectal needle biopsy or transurethral resection or biopsy specimens. The differential diagnosis includes both stromal sarcomas arising from specific prostatic stroma, including STUMP (stromal tumors of uncertain malignant potential), and sarcomas of soft tissue-type, such as inflammatory myofibroblastic tumors, malignant peripheral nerve sheath tumors, leiomyosarcoma, and other types of rhabdomyosarcoma (alveolar and pleomorphic).<sup>2</sup> Occasionally GIST from the

rectum invading the prostate might also be a consideration. Immunohistochemistry is of utmost importance in ascertaining the correct diagnosis, which is based on immunopositivity for desmin and skeletal muscle markers (MyoD1, myogenin, fast myosin, sarcomeric actin, myoglobin, ...). Predictive prognostic factors are stage-related. Adults with prostatic rhabdomyosarcomas do not respond to multimodal therapy and have a poor prognosis. Pediatric patients appear to respond much better than adults with combined modality treatment for sarcoma in general<sup>3-5</sup>, and the rhabdomyosarcomatous group fares better than the non-rhabdomyosarcomatous one.<sup>3</sup> All adult patients with adequate follow-up died within 20 months after histological diagnosis with a mean survival of 8 to 10 months versus an overall 5-year survival rate of 70-80% and a median survival of over 10 years, respectively, in children.<sup>3</sup> Surgery is the mainstay of treatment.

In conclusion, ERMS of prostate in adults is a very rare and aggressive disease. The long-term disease specific survival rate is poor. Stage influences the outcome. Early diagnosis and complete surgical resection offer the patients the best chance of improved survival.

#### References:

1. Waring PM, Newland RC. Prostatic embryonal rhabdomyosarcoma in adults. A clinicopathologic review. Cancer. 1992;69:755-762.
2. Hansel DE, Herawi M, Montgomery E, Epstein JI. Spindle cell lesions of the adult prostate. Mod Pathol. 2007;20:148-158.
3. Janet NL, May AW, Akins RS. Sarcoma of the prostate: a single institutional review. Am J Clin Oncol. 2009;32:27-29.
4. Sexton WJ, Lance RE, Reyes AO, Pisters PW, Tu SM, Pisters LL. Adult prostate sarcoma: the M. D. Anderson Cancer Center Experience. J Urol. 2001;166:521-525.
5. Mondaini N, Palli D, Saieva C, Nesi G, Franchi A, Ponchietti R, et al. Clinical characteristics and overall survival in genitourinary sarcomas treated with curative intent: a multicenter study. Eur Urol. 2005;47:468-473.

# AMR SEMINAR #59

## CASE 4

**Contributed by:** Michele Bisceglia, M.D. (slides labeled 79501-92 and MB-660).

**Clinical History** (1<sup>st</sup> part) (A) 79501-92: In August 1992 a 59-year-old Caucasian man was hospitalized for abdominal discomfort, back pain, and weight loss. CT scan revealed a huge left adrenal mass. Left adrenalectomy with ipsilateral nephrectomy was performed and the surgical specimen sent for pathological examination. Macroscopically the tumor had ill-defined outlines and was hard in consistency. On sectioning it was mainly solid with pseudocystic cavities and showed greyish color with alternating brown to yellowish areas. The periadrenal and perirenal fat tissue was infiltrated by tumor. Histologically (slide labelled 79501-92) the tumor was composed of intersecting bundles of uniform short spindle cells admixed with inflammatory cells, mainly lymphocytes and plasma cells. Mitoses were numerous. Coagulative necrosis was a prominent feature. Immunohistochemically: vimentin was diffusely positive, common actin and alpha-smooth muscle actin were focally weakly positive, desmin and S-100 protein were negative.

**Diagnosis.** In summary, a diagnosis of retroperitoneal leiomyosarcoma, with inflammatory features, involving the adrenal gland, was then rendered. *(At that time I was aware that Chris Fletcher was working on an entity or sarcoma subtype he would call inflammatory leiomyosarcoma – the paper followed 3 year later by Merchant W, Calonje E, Fletcher CD. Inflammatory leiomyosarcoma: a morphological subgroup within the heterogeneous family of so-called inflammatory malignant fibrous histiocytoma. Histopathology. 1995;27:525-32).*

**Clinical History** (2<sup>nd</sup> part) (B) MB-660 : In July 2004 our histological glass slides from 1992 were requested by an outside institution for revision. One month earlier the patient had been hospitalized for a huge retroperitoneal tumor encasing the aorta and inferior vena cava. The tumor was assumed to be a recurrence of the 1992 primary. Tumor excision was not feasible and two large wedge biopsies were taken. The diagnosis of "extra-gastrointestinal GIST" was suggested by the outside pathologist, since they got CD34 diffusely and strongly positive and CD117 was diffusely weakly positive. The 1992 paraffin embedded tissue blocks were recut and stained, and unstained glass slides prepared. The day the slides were packaged to be sent out, I was informed that the patient was still alive. This legitimately led to question my previous diagnosis. I asked to revise the 1992 case myself, and this time only based on morphology I could reverse my previous diagnosis of inflammatory leiomyosarcoma in that of "atypical Kaposi's sarcoma involving the adrenal"). The same day 2 extra unstained slides, which had been left out of the package for the outside institution, were 1 each immunostained for KIT/CD117 and HHV8, the former to demonstrate the tumor was not a GIST, the latter to confirm the new morphological diagnosis of Kaposi's sarcoma. CD117 was totally negative, while HHV8 was diffusely positive in tumor cell nuclei. This confirmed the diagnosis of "retroperitoneal Kaposi's sarcoma". The new diagnostic report was attached to the package of slides the day after, ready to be delivered to the patient's relatives, along with an accompanying letter for the outside institution. Then, I had immunohistochemical stains completed, which were as follows: CD34 strongly positive, CD31 moderately positive, CD21 negative. The HIV test was performed at this time which was negative. The outside institution sent the slides for a third opinion to the referral Italian Center for Soft Tissue Tumors and the diagnosis of Kaposi's sarcoma was confirmed.

The histological glass slides relevant to the tumor recurrence were also personally reviewed (slide labelled MB-660). The tumor was apparently malignant with a high mitotic index (10M out of 10HPF), cytologic atypia and necrosis. We performed immunostains in our laboratory and the tumor was again strongly positive for vimentin and CD34, weakly positive for c-KIT/CD117, focally positive for S-100 protein (however most cells were Langerhans cells), and negative for desmin and alpha-SMA.

**Final Diagnosis:** *Primary tumor* – Retroperitoneal atypical sporadic Kaposi's sarcoma involving the adrenal.  
**Recurrence** – Sarcomatous transformation of recurrent Kaposi's sarcoma.

**Follow-up:** This patient became severely debilitated and died after few months

**Discussion:** Kaposi's sarcoma (KS) is a peculiar tumor of vascular derivation and viral etiology (gammaherpesvirus HHV-8), occurring primarily in the skin. KS is rare, comprising 0.1% of all malignancies worldwide. A variety of clinical

forms have been identified: the sporadic, the endemic, the iatrogenic, and the epidemic. The sporadic (or classical, European, Mediterranean) form primarily affects elderly Caucasian males with a predisposition for Eastern and Southern Europeans, and Jews of European (mainly Russian and Polish) and North African origin. KS mostly affects the skin of the acral sites, having a chronic and indolent clinical course and persisting for many years, with little propensity to spread to other organs. In most cases the course is benign, but a fatal outcome after many years has also been observed. In sporadic KS soft tissue, bone, lymph nodes, and visceral organs (mainly the gastrointestinal tract) are rarely involved. On occasion these unusual locations represent the only site of involvement. At the time I observed this tumor I already had a moderate experience with this type of tumor: in fact in 1991 I led a paper dealing with around 150 cases of sporadic Kaposi's sarcoma<sup>1</sup> and was well aware of unusual occurrences as documented by the observation we did of Kaposi's sarcoma of lymph node in a HIV-negative boy<sup>2</sup> (the second such case at that time – parenthetically also the first case of Kaposi's sarcoma in lymph node in a child which had been reported by other authors in the literature was also Italian). Still this tumor fooled me. The main reason I believe was the fact that it occurred in a “very” unusual location, not described yet at the time this case was first observed. However in 2001 a case of exclusive bilateral adrenal gland involvement by (histologically) classical Kaposi's sarcoma has been subsequently reported in an HIV-seronegative young black male patient (of 17-years of age).<sup>3</sup> Another reason is in my opinion the atypical histological features exhibited by this tumor (absence of erythrocyte in the slit-like spaces, absence of hyaline globules, extensive necrosis, a more accentuated spindling of tumor cells, focal fascicular arrangement of tumor cells).

**Comments:** This is a case of apparently exclusive adrenal/retroperitoneal Kaposi's sarcoma in a non-HIV patient. Adrenal gland involvement in association with many other localizations has been reported occasionally in AIDS-related Kaposi's sarcoma and only in 1 case of non-HIV related Kaposi's sarcoma of the adrenal gland (see above). KS of any clinical form may occur in any organ, included brain. The unusual site of occurrence of this case emphasizes the importance of keeping in mind the metaphoric “man of Istanbul” so beautifully described by Juan Rosai.<sup>4</sup> In most cases of Kaposi's sarcoma the course is benign, but a fatal outcome after many years has also been observed (and parenthetically I can say having seen another case of fatal outcome of sporadic Kaposi's sarcoma who after around 30 years he suffered by a bone Kaposi's sarcoma on the lateral malleolus, then developed lung and brain localizations). In difficult cases, the detection of human herpesvirus type 8, either by molecular analysis (Herpes virus-8 DNA detection by PCR), in situ hybridization, or immunohistochemistry, is crucial. Atypical histological forms can occur in usual and unusual sites. To date this case of adult HIV seronegative male patient with unilateral adrenal involvement is the first such case in a Caucasian patient.

#### References.

1. Bisceglia M, Bosman C, Carlesimo OA, Innocenzi D, Quirke P. Kaposi's sarcoma: a clinico-pathologic overview. Tumori. 1991;77:291-310.
2. Bisceglia M, Amini M, Bosman C. Primary Kaposi's sarcoma of the lymph node in children. Cancer. 1988;61:1715-1718.
3. Lazure T, Plantier F, Alsamad IA, Cabanis P, Malaury E, Blondeau JR. Bilateral adrenal Kaposi's sarcoma in an HIV-seronegative patient. J Urol. 2001 Nov;166(5):1822-3.
4. Rosai J. Dr. Lauren V. Ackerman and his man from Istanbul. Semin Diagn Pathol 20(4):247-248, 2003

# AMR SEMINAR #59

## CASE 5

**Contributed by:** Michele Bisceglia, M.D. (slides labeled 2-163876-8/A and 2-163876-8/B).

**Clinical History:** A 22-year-old Caucasian short man, 155 cm high (weight 65 kilos) was hospitalized, complaining of medical, anatomical, and psychosocial problems relating to a history of 10 year duration of a recurrent keloid. The patient's standing and walking were impaired and he needed assistance in coping with stairs. At physical examination a huge, bulging, oval mass with a knobby surface 45 cm in length (20 cm wide; 10 cm thick) was apparent on his lower back. The mass was firm in consistency and covered by skin which was focally eroded or moist with evil-smelling secretions, and occluding the anus. Physical examination also revealed a nodular exophytic mass 5 cm in size, protruding from the umbilical scar, which appeared two years earlier. No other physical deformities were seen. His hands and fingers as well as his feet and toes were normal. Past medical history revealed excision of an intergluteal and perianal, subcutaneous fibrolipoma of 2 cm in size at the age of 11, which was histologically examined. At the age of 12 and at the age of 14, he was hospitalized in specialized centers for surgical plastic reconstruction and underwent second and third surgical excisions due to keloid formations of 4 cm and 10 cm in size, respectively. A new keloid became evident shortly afterwards, which was at times treated with steroid injections without success. The tumor mass progressively enlarged reaching the above dimensions. The preoperative clinical suspicion was that of a sarcomatous growth, which was confirmed by means of PET-CT investigation, but needle biopsy did show a reactive proliferation of fibroblasts and myofibroblasts alternating with abundant acidophilic bands of collagen, typical of keloid. Simultaneously the patient received genetic counselling and endocrinological evaluation, which showed a normal male karyotype, and excluded keloid-associated genetic syndromes, familial history of keloidal formation, and diabetes mellitus. The patient also underwent neurological examination since he had been diagnosed with primary epilepsy at the age of 5, which was confirmed, and was taking oral anticonvulsant drugs (Depakine, Gardenal) for prophylaxis and maintenance since. The tumor mass was surgically extirpated *en bloc* (weight 3.400 gr) and sent for pathological examination (slides enclosed). The surgical wound was repaired with a plastic reconstruction operation.

**Diagnosis:** Pathological examination confirmed the diagnosis of recurrent, giant keloid of the sacral region, which was still focally present at the lateral excision margins.

**Follow-up:** 60 days after surgery radiotherapy was undertaken using photon 8MW. (total dose delivered 22Gy in 11 days, with a daily fraction of 2 Gy). The umbilical keloid was not treated since surgery was not necessary and due to the patient's predisposition to keloid formation. No recurrence has been noticed so far 24 months after this combined treatment (surgery plus post-surgical radiotherapy).

**Discussion:** Keloid is an abnormal pattern of dermal reaction to injury, resulting in excess collagen deposition, affecting 5 to 10% of general population. Various types of injuries are on record, such as surgery, trauma, burns, inflammatory skin diseases (folliculitis, acne), viral dermatological diseases (chicken pox), vaccinations (Calmette-Guerin/BCG, small pox, and hepatitis B), fish stings (catfish), foreign bodies. Occasionally the injury may be clinically inapparent. The pathogenesis is unknown, but genetic, hormonal, or local factors may be involved. Keloids may occur at any age, but they are more common in the young. Black people are more frequently affected. It is usually sporadic, but familial occurrences have also been described.<sup>1</sup> There's no sex prevalence among affected individuals. They can be either solitary or numerous, and may vary in size from small papules to large masses. Symptoms may vary from mild local distress (pain, pruritus) to cosmetic discomfort or anatomic disabilities, even to disfiguring deformities, associated with dramatic psychological and social side-effects. No universally accepted treatment protocol has been standardized, but several choices are available according to several factors (site, size, clinical history, prior treatments). Keloids are often resistant to treatment and have a high rate of recurrence.<sup>2</sup> Giant keloids are extremely rare with only 6 cases recorded in the literature, the largest reaching the size of 20 cm in its greatest diameter, all of which with a known history of injury, including unusual etiologies (chicken pox<sup>3</sup>, cat-fish sting, vaccination with BCG 1 case each), except 1 case with no attributed inciting cause<sup>4</sup>: the latter case was also the only arising in a familial context. Three cases showed multiple lesions of various dimensions. Although unique as to the size and deformity caused, our case can be categorized as one of the common sporadic cases: non-endocrine, since no endocrinological abnormalities was recognized, non-familial, since no keloidal inheritance pattern in his pedigree was ascertained, non-syndromic, since no stigma of keloid-associated syndromes (e.g., Rubinstein-Taybi syndrome)



or of the disfiguring (infantile) hyaline fibromatosis were seen, and non-druggable, since the absence of any plausible role in keloidal proliferations. Instead the inciting factor was well identified as the first surgical trauma which triggered a likely individual genetic predisposition to keloid formation. The histological differential diagnosis include keloidal dermatofibroma, desmoplastic fibroblastoma (collagenous fibroma), hyaline fibromatosis. The case presented herein is the largest one ever observed, and one with most dramatic psychological impact (the patient lived almost in isolation due to shame of the disease).<sup>5</sup> Keloids have been shown to respond to radiotherapy, pressure therapy, cryotherapy, intralesional and topical injections of corticosteroids, interferon and bleomycin or fluorouracil, topical silicone or other dressings, and laser treatment used alone or in various combinations, with variable but largely transient success.<sup>6,7</sup> Surgery has been used in case of necessity. Primary radiation therapy has been used for unresectable keloids.<sup>8</sup> The combination of surgery and postsurgical radiotherapy has already been proposed for cases where surgery is required, and has already been effectively used (follow-up >2 years) in another case of giant keloid.<sup>4</sup> Giant keloids are extremely rare, and they may respond to a combined approach (surgery plus postsurgical radiotherapy).

#### References:

1. Marneros AG, Norris JE, Olsen BR, Reichenberger E. Clinical genetics of familial keloids. *Arch Dermatol.* 2001;137:1429-1434.
2. Alster TS, Tanzi EL. Hypertrophic scars and keloids: etiology and management. *Am J Clin Dermatol.* 2003;4:235-243.
3. Gathse A, Ibara JR, Obengui, Moyon G. [Gigantic keloids after chicken-pox. A case report] *Bull Soc Pathol Exot.* 2003;96:401-402.
4. Jones K, Fuller CD, Luh JY, Childs CC, Miller AR, Tolcher AW, et al. Case report and summary of literature: giant perineal keloids treated with post-excisional radiotherapy. *BMC Dermatol.* 2006;6:7. DOI:10.1186/1471-5945-6-7.
5. Furtado F, Hochman B, Ferrara SF, Dini GM, Nunes JM, Juliano Y, et al. What factors affect the quality of life of patients with keloids? *Rev Assoc Med Bras.* 2009;55:700-704.
6. Juckett G, Hartman-Adams H. Management of keloids and hypertrophic scars. *Am Fam Physician.* 2009;80:253-260.
7. Mutalik S. Treatment of keloids and hypertrophic scars. *Indian J Dermatol Venereol Leprol.* 2005;71:3-8.
8. Malaker K., Vijayraghavan K., Hodson I., Al Yafi T. retrospective analysis of treatment of unresectable keloids with primary radiation over 25 years. *Clinical Oncology* 2004; 16: 290–298.

# AMR SEMINAR #59

## CASE 6

**Case contributed by:** Ira Bleiweiss, M.D.

**Short Summary:** 74-year-old female with history of breast cancer, now presenting with anemia.

**Case Description:** This 74-year-old female had a history of breast cancer almost 4 years earlier. She had 2 right breast masses - invasive lobular carcinoma, pleomorphic and signet ring cell types, 2.5 cm and 2.7 cm. Modified radical mastectomy was performed and there were three positive lymph nodes, each showing only individual and clustered tumor cells identified only on cytokeratin stains. She received Adriamycin, Cytoxan, and Taxotere.

She now presents with intractable anemia, despite numerous blood transfusions. Upper and lower endoscopy were negative, and only a capsule endoscopy revealed an ulcerating mass in the small intestine. During the workup, multiple bone lesions were identified, one of which was biopsied revealing metastatic lobular carcinoma, and a mass in the head of the pancreas was also found, FNA'd and suspicious for malignancy.

The slide is obviously from the resection of the small bowel tumor which was grossly 6x4 cm, ulcerating and invading the full thickness of the bowel wall. Histologically it is composed of both spindle cell sarcomatous areas and epithelioid areas, so called sarcomatoid carcinoma of the small bowel - but wait ---there's more....

**Discussion:** This case was sent to me as a consultation because the oncologist couldn't believe the diagnosis. Here's why...the pathologist at the original hospital correctly performed immunohistochemical stains for keratins to evaluate the tumor and prove the diagnosis- this provided a surprise - individual and clustered keratin positive cells in the serosa (image 1 on the website). Given the invasive lobular breast cancer history, he then stained for estrogen receptor and guess what---ER positive (image 2 on the website) and GCDFP-15 positive (both negative in the sarcomatoid carcinoma). A lymph node was also positive (image 3 on the website).

Look carefully at the serosa, and you'll see rare foci of metastatic lobular carcinoma as clusters of large signet ring cells. I myself would admittedly never have noticed them were it not for the immuno - the main tumor is too distracting and rare enough on its own. My congratulations to any of you who picked up on the metastatic lobular.

**Diagnosis:** Collision of metastatic lobular carcinoma of breast with primary sarcomatoid carcinoma of the small bowel.

**Follow-up:** About 4 months after the surgery, the patient suffered a stroke. She expired in hospice 4 months after the stroke. The pancreatic lesion was never pursued, nor was an autopsy performed.

# AMR SEMINAR #59

## CASE 7

**Contributed by:** Kum Cooper, Vermont, USA

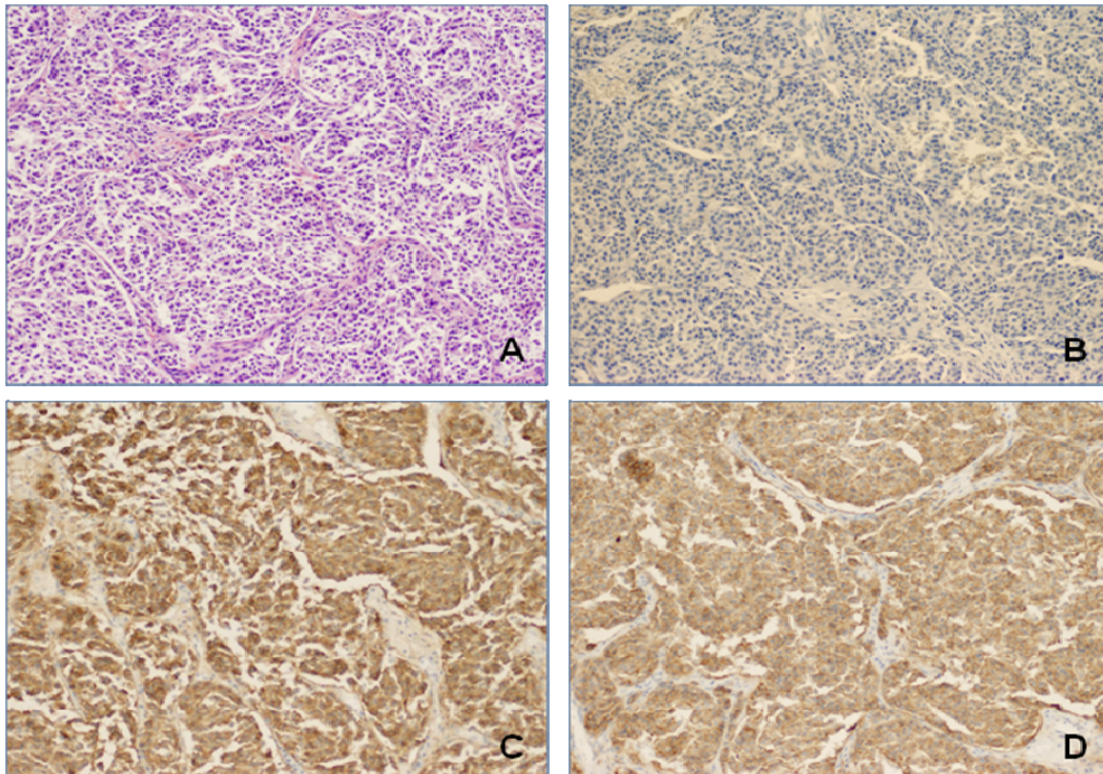
**Clinical History:** 27-year-old male with worsening headache and left arm numbness and weakness for two days.

**Radiology:** CT scan/MRI showed a right-sided 2.0 x 3.5 cm heterogeneous frontoparietal tumor with a broad dural attachment and expansion into the inner table of the skull.

**Immunohistochemistry:** C-kit positive, DOG-1 positive, EMA negative (see images).

**Diagnosis:** Metastatic GIST.

**Comment:** The whirling morphology, organoid pattern and dural attachment, along with the site of the lesion is a “no-brainer” for meningioma. This is my response to David’s “man in Istanbul”. This patient apparently had a primary GIST diagnosed in 2001, metastatic to the liver and lung in 2003 with a neurological presentation in September 2010 (submitted representative slide). I’m afraid that I do not have the primary morphology nor the mutational status to provide you, suffice it to say that I was pleased not to have been on brain frozens when this arrived in our department! (Please view the IHC on the website.)



Metastatic GIST Mimicking Meningioma. A. Whirling morphology. B. EMA negativity. C. C-Kit (CD117) positivity. D. DOG-1 positivity.

# AMR SEMINAR #59

## CASE 8

**Contributed by:** Ivan Damjanov, M.D.

**Clinical History:** A 23-year-old woman with history of recurrent malignant melanoma of the leg.

**Pathologic Features:** The dermis contains foci of malignant melanoma with areas of ossification. Tumor cells were positive for s100 and negative for "melanoma cocktail".

**Comment:** The original melanoma, which was removed a year ago did not contain foci of ossification. For the time being, 5 months after the last surgery, the patient is free of tumor.

**Discussion:** This case is included for "your viewing pleasure". We have never seen before a malignant melanoma with osteogenic metaplasia, but as you could predict, once we started looking up the literature some papers written by the members of the AMR Seminar group started to pop up ( Fukunaga M :Osteogenic melanoma, APMIS 2005; 113: 296-300; Mentzel T: Uncommon variants of malignant melanocytic neoplasms. Pathologie 2007;28: 445-452 [in German] ).

Osteogenesis in a recurrent malignant melanoma was first reported by Urmacher (Am J Dermatopathol 1984;6:331-335). The best reference in English is the paper by Masa Fukunaga, a truly scholarly discourse about this unusual microscopic form of melanoma, and the possible mechanisms of osteogenesis in this tumor. It is of interest to note that Dr. Fukunaga could not find more than 19 published cases of osteogenic melanoma in the literature till 2005. I did not consult Dr. Mentzel's paper, but maybe he can add his comments personally. I would not be surprised if some or most of you have seen this type of melanoma, but we could not find any similar cases in our files in Kansas.

# AMR SEMINAR #59

## CASE 9

**Contributed by:** Otto Dietze, M.D.

**Case History:** 50-year-old patient underwent hysterectomy and lymph node dissection for endometrial carcinoma and lymph node dissection. (pT 1a, pN 0 G2). In several nodes (iliac. ext + int. sin., iliac. int. dex. iliac.com. and fossa obtur. sin.) small spindle cell infiltrates were detected

**Diagnosis:** Lymph node involvement by lymphangioleiomyomatosis (LMA)

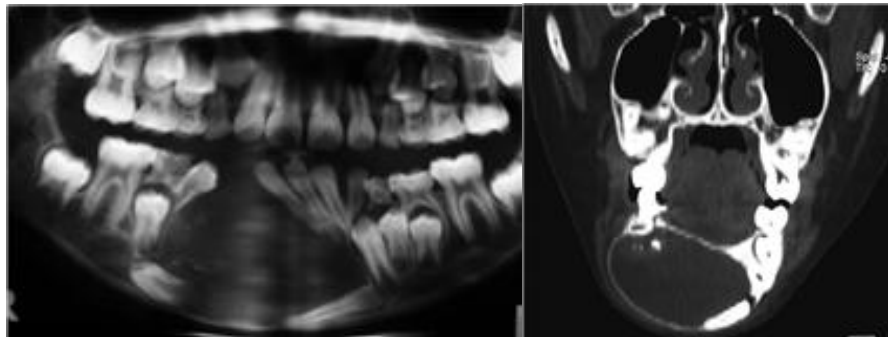
**Comment:** There is nothing to add to Michele's careful presentation and description of this entity in the last seminar. However, hitherto there is no clinical evidence of other organ involvement, esp. the lung. I could not find a similar interesting case within the last year in my files, except a case of mesonephric adenocarcinoma in the vulva, a tumor, which was also presented a few seminars ago (in the cervix) If any one in the club is interested to collect a larger number of cases, I of course can offer him paraffin material of both tumors

# AMR SEMINAR #59

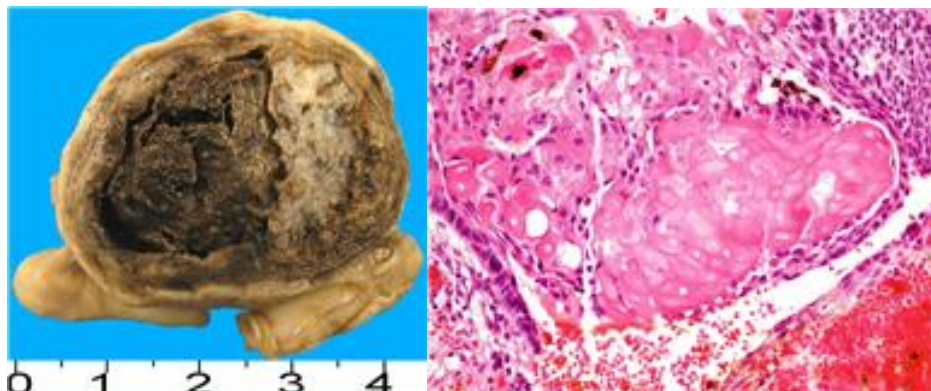
## CASE 10

**Contributed by:** Hugo Dominguez Malagon, M.D.

**Clinical History:** A 9 year-old male with a slowly progressive growth of the incisor mandibular region, A plain radiograph and CT scan demonstrated an intraosseous tumor, apparently cystic, with internal irregular opacities with lateral displacement of the adjacent teeth producing tooth divergence. The tumor was resected in block.



**Pathological Findings:** Grossly the tumor had a cystic appearance with a single cavity filled with red brown coagulated material, the wall was of variable diameter with intramural and intracavitary pale nodules with a petrous consistency. Histologically the neoplasia is mostly cystic, lined by epithelial cells partly squamoid and many basaloid with peripheral palisading focally forming stellate reticulum. There are nests of "ghost cells" (shown in the picture). In many areas focally shown in the submitted slide, dentinoid matrix was present.



**Diagnosis:** CALCIFYING CYSTIC ODONTOGENIC TUMOR (GORLING CYST).

**Comment:** I wanted to send a nice classical case of CCOT, it has the classical location in the incisor zone, radiographs are very characteristic and it shows most of the histological features of this rare neoplasm. Many surgical pathologists do not have the chance to see this type of lesions, mostly seen in specialized centers. CCOT may be intraosseous or extraosseous, the differential diagnosis include unicystic ameloblastoma and Dentinogenic ghost cell tumor that behave more aggressively. CCOT is a benign tumor usually cured by local excision but few recurrences have been reported.

# AMR SEMINAR #59

## CASE 11

**Contributed by:** Vincenzo Eusebi, M.D. (Case n. 09-17928)

**Case Description:** A 51- year-old lady with a subcutaneous nodule of the left hip.

**Clinical Information:** Intracranial tumour (longitudinal sinus) operated 13 years earlier. The diagnosis of meningeal hemangiopericytoma was obtained . The intracranial tumour has recurred after 5 and 7 years. The slide number 03 –23778 is the recurrence after 7 years. All tissues examined are very similar including BCl2 and CD 99 positivities and Ki 67 present in about 20% of cells in all lesions . CD 34 is weakly positive in the intracranial lesions and negative in the subcutaneous nodule . As all lesions removed are identical, we have interpreted the subcutaneous nodule as a metastasis from the intracranial recurrent tumour.

The present case (case n. 8) has been included in a series of meningeal hemangiopericytomas (Virch Archiv 456: 343-354, 2010). In this series, meningeal hemangiopericytomas recurred in 13 out of 14 cases. One case only (the present one) gave a metastasis.

# AMR SEMINAR #59

## CASE 12

**Contributed by:** Cyril Fisher, M.D., Royal Marsden Hospital, London, UK

**Clinical History:** A 58-year-old female with a history of pANCA-positive vasculitis was found to have an incidental small renal mass. This was monitored over several years as it slowly enlarged. When the tumor exceeded 2cm in diameter a laparoscopic nephrectomy was performed.

**Pathology:** The gross specimen was a spongy vascular mass 2.3 cm in diameter that appeared to abut the renal parenchyma in the renal sinus and involve the main renal vein. There were also multiple small (<1cm) indistinct hemorrhagic areas in the renal parenchyma, which were separate from the main hilar tumor. Microscopically, there is a multinodular cellular angiomatous lesion with focally dilated or sinusoidal, sometimes anastomosing vessels, with occasional plump endothelial cell nuclei, thrombi, hyaline globules and foci of extramedullary hemopoiesis. The lesion extends irregularly into fat and into blood vessels.

**Diagnosis:** Anastomosing hemangioma of kidney.

This is a vascular tumor in the genitourinary tract recently defined in a series of 6 cases by Drs Montgomery and Epstein.<sup>1</sup> Most cases occur in males and involve kidney or renal hilum. Additional microscopic features that can be seen include central sclerosis and focal necrosis but mitoses are usually absent and there is no significant cytologic atypia or multilayering, aiding the distinction from angiosarcoma. Notwithstanding the intravascular extension, none of the cases with follow up recurred or metastasized. Five cases with anastomosing pattern (but lacking extramedullary hemopoiesis) have been reported as part of a multicenter study of 25 renal vascular lesions.<sup>2</sup>

### References:

1. Montgomery E, Epstein JI. Anastomosing hemangioma of the genitourinary tract: a lesion mimicking angiosarcoma. *Am J Surg Pathol* 2009;33;1364-1369.
2. Brown JG, Folpe AL, Rao P *et al*. Primary vascular tumors and tumor-like lesions of the kidney: a clinicopathologic analysis of 25 cases. *Am J Surg Pathol* 2010;34;942-949.



# AMR SEMINAR #59

## CASE 13

**Contributed by:** Christopher Fletcher, M.D.

**Clinical History:** While undergoing work-up for an intestinal problem, a 78-year-old man was found to have an incidental well-circumscribed 10 cm mass located in perirenal fat within the retroperitoneum.

**Diagnosis:** Sclerosing PEComa.

**Comments:** This very distinctive variant of PEComa seems to occur almost exclusively in the retroperitoneum, often close to the kidney, although one may see much smaller areas of sclerosis in PEComas at other sites. The large majority of these sclerosing lesions occur in women and are entirely benign and I have encountered only one malignant example. One can appreciate that the tumour cells in this case, whether ovoid, epithelioid or spindled, have characteristically rather granular eosinophilic cytoplasm and vesicular nuclei. In many areas, the tumour cells are arranged concentrically around vascular lumina and appear to 'spill off' vessel walls. The lesional cells in this case, as anticipated, showed multifocal positivity for both SMA and HMB45.

**Reference:**

Hornick JL, Fletcher CD. Sclerosing PEComa: clinicopathologic analysis of a distinctive variant with a predilection for the retroperitoneum. Am J Surg Pathol 2008; 32:493-501.

# AMR SEMINAR #59

## CASE 14

**Contributed by :** Andrew Folpe, M.D.

**Case Description:** A 62-year-old woman underwent a right knee total arthroplasty for severe degenerative joint disease.

**Pathological Findings:** The submitted sections show relatively typical features of severe degenerative joint disease, with cartilage loss and fissuring, subchondral cyst formation, and associated synovitis. A somewhat unusual feature was the presence of increased numbers of neutrophils, principally in a subchondral location adjacent to the subchondral cysts.

**Diagnosis:** Subchondral acute inflammation in severe arthritis (Am J Surg Pathol 1999; 23: 192-7)

**Comment:** I realize that many of you are scratching your heads as to why I have chosen to submit such a prosaic case to this exotic slide club. Fundamentally, my problems with this case arose from my own ignorance, as I was shockingly unaware of the above paper from John O'Connell, Petur Nielsen and Andrew Rosenberg until after I had looked at this case. It was submitted in consultation with a suggested diagnosis of acute osteomyelitis as an incidental finding in a patient with DJD. I was confident that the inflammatory process was entirely related to the arthritis, but I was having a distinctly difficult time persuading the contributor of this. I happened to be emailing with Petur Nielsen about an unrelated issue at this time, and "vented" to him about this particular contributor. Petur was then nice enough to direct me to his paper, which quite clearly shows this pattern of subchondral acute inflammation to be unrelated to infection, most likely representing a reaction to insudated synovial fluid. Armed with this reference, I was finally able to persuade the contributor not to diagnose this patient with osteomyelitis.

# AMR SEMINAR #59

## CASE 15

**Contributed by:** Jerónimo Forteza Vila, M.D.

**Clinical History:** 49-year-old woman with no medical history of interest. She went to the gynecologist with abundant genital bleeding, which had been almost continuous for the previous two months. Myomatous uterus was suspected after an ultrasound. A total hysterectomy and double annexectomy were performed.

Two years after the intervention she presented dyspnea that was not associated with cough, sputum, fever or any other clinically relevant symptoms. In an x-ray of the thorax there appeared multiple bilateral pulmonary nodules, dispersed throughout all lobules, with peripheral distribution, the largest was 13 mm in diameter, and radiological suggestion was pulmonary metastasis. Neither pleural hemorrhaging nor mediastinitic adenopathies were appreciable.

An atypical resection of all nodules was performed through a thoracotomy in two stages. A total of 27 nodules from the right lung and 30 nodules from the left lung were sent for a histopathological study.

**Pathological Findings:** The piece from the total hysterectomy and double annexectomy weighted 436 g. and measured 11x8x6.5 cm. The endometrial cavity was occupied by a nodular formation with slightly defined edges, it measured 5x3.5 cm and penetrated the myometrial wall without affecting the endocervix. Both annex were of normal appearance.

The histopathological study of the lesion showed a densely cellular tumor, composed of spindle-shaped and oval cells, without nuclear atypia, pleomorphism or mitosis. They were accompanied by a striking net of small arteriole (capillaries). Images of vascular and myometrial invasion were identified, but neither necrosis nor hemorrhaging was observed. No areas with other type of histological differentiation were found either. The immunohistochemistry study in the neoplastic cells was positive for vimentin, CD10, smooth-muscle actin, estrogen receptors and progesterone receptors. CKAE1AE3, desmin and HHF35 were negative. The proliferation index, measured with Ki67, was 4%.

The 57 pulmonary nodules that were examined show similar macroscopic and microscopic characteristics. They were nodular lesions, well defined, whitish, with slightly swirled surface.

Histologically, they were composed by atypical fusiform cells, which remind us of smooth-muscle normal cells. Neither mitosis nor necrosis was appreciated.

They all presented immunostaining with smooth-muscle actin, smooth-muscle myosin, desmin, HHF35, estrogen receptor and progesterone receptors.

**Diagnosis:** Pulmonary leiomyomatosis in patient diagnosed with sarcoma of the endometrial stroma with low level of malignancy.

**Discussion:** The principal problem we have with this case is the differentiation between metastatic or primary pulmonary illness, since it is of great relevance for the patient, both clinically and for prognosis.

Given the precedent sarcoma of the endometrial stroma, the finding of multiple pulmonary nodules suggests metastasis. However, the histological aspect of the nodules reminds us of a primary tumor. They look like leiomyomas with some hyalinization, just as those of the endometrium. One option is that the appearance of sarcoma of the endometrial stroma had changed in the pulmonary metastasis, changing the immunohistochemistry profile as well. Nevertheless, it seems more reasonable that it is a pulmonary leiomyomatosis, developed by estrogen stimulus and that it is not related to the uterine tumor. On the other hand, in a sarcoma of the endometrial stroma that extends outside of the uterus, one would expect to find pelvis metastasis, in addition to pulmonary metastasis.

Note: we attached histological preparation (HE) of one of the pulmonary nodules and pictures representative of the uterine lesion.

# AMR SEMINAR #59

## CASE 16

**Contributed by:** Allen Gown, M.D.

**History:** Patient is a 46-year-old female, with a history of infiltrating ductal carcinoma of the breast in 2003, who now presents with an enlarging uterine mass measuring 12.5 cm in greatest extension, with foci of necrosis and hemorrhage noted grossly. The mass involved the entire uterus with nodules also present on the serosal surface.

**Pathology:** The tumor cells are modest in size, somewhat epithelioid, but without any growth pattern than can be described other than sheet-like, with intervening areas of necrosis. In some areas the cytoplasm of the tumor cells does have some clear cytoplasmic features, but this may represent an artifact. Results of the most relevant immunohistochemistry studies are as follows:

Cytokeratin (using pankeratin antibody, OSCAR): Negative  
Smooth muscle actins: Focally positive  
Desmin: Uniformly positive  
S100: Negative  
Synaptophysin : Negative  
Myogenin: Negative  
Beta catenin: Positive for high levels of nuclear expression  
CD10: Negative

**Diagnosis:** Desmoplastic small round cell tumor confined to uterus.

**Comment:** Negative cytokeratin studies appeared to rule out the diagnoses of metastatic breast cancer or a primary GYN carcinoma, and along with the negative S100 studies, these overall results appeared to point to the diagnosis of sarcoma, although its exact subclassification was initially uncertain, with the immunohistochemistry studies yielding conflicting results. The uniform nuclear expression of beta catenin, in this clinicopathologic setting, initially suggested the diagnosis of endometrial stromal sarcoma, one of the few sarcomas that can manifest high levels of nuclear beta catenin expression (1). And as described by Sumathi et al. (2) desmin expression can be seen in a subset of endometrial stromal sarcomas. However, beta catenin results notwithstanding, the uniform desmin positivity raised the alternative possibility of the diagnoses of leiomyosarcoma or even rhabdomyosarcoma (i.e., as part of a mixed Müllerian tumor). There was only very focal smooth muscle actin expression, however, and the negative myogenin studies (along with MyoD1) argued persuasively against these latter diagnoses.

At this point the favored diagnosis still appeared to be endometrial stromal sarcoma, but additional fluorescence in situ hybridization (FISH) studies were performed using a breakapart probe to the EWSR gene, and found to be positive. However, the diagnosis was still uncertain, as translocations involving EWSR have been found in a subset of sarcomas, including: desmoplastic small round cell tumor (DSRCT), Ewing's sarcoma/PNET, clear cell sarcoma, angiomatoid fibrous histiocytoma, extraskeletal myxoid chondrosarcoma, and a subset of myxoid liposarcoma (3). Based on the overall immunophenotype, most of these tumors could be excluded; strong desmin positivity, however, has been described DSRCT [along with an absence of concomitant cytokeratin in some (4)] and angiomatoid fibrous histiocytoma. Because the location and histology of this tumor did not specifically support either of the latter diagnoses, and given the absence of published data on the presence of EWSR translocations in endometrial stromal sarcoma, RT-PCR studies were performed to identify the 'partner gene' for this translocation involving the EWSR gene on chromosome 22. Indeed, RT-PCR studies demonstrated that this tumor manifested a t(11;22)(p13;q12)] translocation resulting in an EWSR1-WT1 fusion transcript, and was negative for the presence of the PNET/ES associated fusion transcripts, confirming the diagnosis of DSRCT.

DSRCT is a relatively uncommon aggressive malignancy that classically occurs in the abdomen or pelvis of young adults, with a male preponderance. Often the lesion is composed of solid nests of small cells with an intervening dense stroma; one of the diagnostic features of this tumor is the co-expression of cytokeratin and desmin (along with

vimentin). However, Ordonez demonstrated in a series of 39 tumors that DSRCTs could manifest more protean histologic appearances, including spindle cell, rhabdoid, and clear cell, and patterns resembling neuroblastoma, transitional cell carcinoma, and even carcinoid tumors (5). A companion paper documented variable expression of neural markers such as CD57, synaptophysin, chromogranin, etc. along with more consistent cytokeratin and desmin co-expression (6). However, DSRCT is another example of a malignant tumor without a normal counterpart cell, and the value of the immunophenotype beyond documentation of cytokeratin and desmin co-expression is, in my experience, limited. DSRCT is best defined the EWSR-WT1 translocation [t(11;22)(p13;q12)] that results in an EWSR-WT1 fusion gene, as demonstrated in this case. I could not find any published reports containing DSRCTs confined to the uterus.

I'd like to acknowledge Andrew Folpe for his assistance with this case, which appears to be an extraordinary example of a desmoplastic small round cell tumor (DSRCT) that is confined to the uterus.

#### **References:**

1. Ng TL et al., Mod Pathol 18:68-74, 2005.
2. Sumathi VP et al. Int J Gynecol Pathol 23:241-7, 2004.
3. Romeo S, Dei Tos AP. Virchows Arch 456:219-34, 2010.
4. Trupiano JK et al., Mod Pathol 12:849-53, 1999.
5. Ordonez NG. Am J Surg Pathol 22:1314-27, 1998.
6. Ordonez NG. Am J Surg Pathol 22:1303-1313, 1998.

# AMR SEMINAR #59

## CASE 17

**Contributed by:** Janez Lamovec, M.D. (courtesy of: Dr. Barbara Gazić)

**History:** The patient is a 22-year-old woman with a solitary tumor of the left lung. Nine years previously she was treated for autoimmune thyroiditis; three months later enlarged cervical lymph nodes developed but no additional diagnostic procedures were done. However, two months later she appeared with bilaterally markedly enlarged lymph nodes; thyroid was enlarged and firm on palpation. FNAB of lymph nodes and thyroid was performed and a diagnosis of medullary carcinoma or SETTLE was suggested.

The girl was operated in another country and a diagnosis of medullary carcinoma was first given but then revised to SETTLE. Soon after the operation multiple lung metastases developed and a few months later also metastases to two cervical vertebrae. The patient was treated with radio-chemotherapy and a complete remission was achieved. Now, she appeared with a solitary lesion of the lung that was excised.

**Pathological Findings:** Grossly, the excised tumor measured 2 x 1.3 cm and was encircled with a narrow rim of lung tissue. Microscopically, metastasis shows a vaguely nodular structure and is well delineated from the surrounding lung tissue. Tumor cell population is biphasic – spindle cells and plumper more epithelioid cells forming nests and lobules. Transitional forms between the two components are also seen. Tumor cells are focally discohesive forming irregular slits with pseudopapillary projections and “floating” cells. True glandular structures formed by tumor cells are not present. However, in more fibrosed parts of the tumor and among spindle cells innumerable entrapped microcystic, pseudoglandular, tubules-like, and papillary formations lined by cuboid and clear cells of alveolar epithelium and numerous foam cells in lumina are present.

Immunohistochemically, tumor cells were strongly positive for vimentin, smooth muscle actin, CKMNf-116, CKHMW, and CKAE1/AE3 in practically all spindle and transitional cells and in scattered epithelioid cells, CK8 was positive in some spindle cells; CAM5.2, CK7, CK20 were negative and so was EMA, thyroglobulin, TTF-1, S-100 protein, synaptophysin, chromogranin A, and desmin. CD99 and bcl-2 showed focal positive reaction in some tumor cells. CD56 was strongly positive in spindle and epithelioid cells. TTF-1 (see attached microphoto) and EMA clearly decorated cells lining numerous entrapped alveolar structures.

We had the opportunity to see primary tumor (slides sent from abroad – see microphotographs) that was morphologically essentially the same but more fibrosed with some more convincing glandular structures.

**Diagnosis:** SETTLE, metastatic to lung.

**Follow-up:** Recent case.

**Comment:** I thought that this case might be interesting for the group since, I guess, metastatic lesions of this extremely rare tumor are not seen that often. Interesting feature of this tumor is an intimate admixture of hyperplastic preexistent alveolar epithelial structures with tumor tissue giving the impression of the former being an authentic part of the tumor. I am curious to hear comments of experts in the field.

### References:

1. Cheuk W, Jacobsen AA, Chan JK. Mod Pathol 2000; 13: 1150-55.
2. Folpe AL, Lloyd RV, Bacchi CE, Rosai J. Am J Surg Pathol 2009; 33: 1179-86.

# AMR SEMINAR #59

## CASE 18

**Contributed by:** Michal Michal, M.D., Czech Republic

**Clinical information:** Well circumscribed nodule in a 34-year-old male in the parotid gland 16 mm in size. 7 years after the excision the patient was without recurrence and metastases. Genetically we detected ETV6-NTRK3 fusion transcript by RT-PCR method.

**Diagnosis:** Mammary analogue secretory carcinoma of salivary glands, containing the ETV6-NTRK3 fusion gene.

**Comment:** We have been collecting these cases with my colleague from our Department, Alena Skalova, and we have been aware of the existence of this hitherto undescribed entity for nearly 17 years. At first, before being sure that this tumor is a complete analogue of secretory carcinoma of the mammary glands arising in the salivary glands, we called this tumor an S-100 protein positive "weird" acinic cell carcinoma. Virtually all these tumors are S100 protein positive, which is quite rare among the rest of acinic cell carcinomas. With the advent of the possibility for performing ETV6-NTRK3 fusion gene, we confirmed our suspicion of the homology with secretory carcinoma of the breast. The tumors are clinically, histologically and immunohistochemically identical to their mammary gland counterpart; the only clinical difference is that in the salivary glands these tumors occur in adult to old patients and in the mammary glands most of them occur in children or young adults.

### References:

1. Skalova A., Vanecek T., Sima R., Laco J., Weinreb I., Stárek I., Geierová M., Passador-Santos F., Ryška A., Leivo I., Kinkor Z., Michal M. Mammary analogue secretory carcinoma of salivary glands, containing the *ETV6-NTRK3* fusion gene. Hitherto undescribed salivary gland tumor entity. American Journal of Surgical Pathology 2010;34: 599-608



# AMR SEMINAR #59

## CASE 19

**Contributed by:** Markku Miettinen, M.D.

**History:** 5-month-old otherwise healthy baby boy with a polypoid skin nodule at the umbilicus.

**Comment:** This clinically distinctive, small polypoid tumor was described as clinicopathologic entity by Vargas in 1991. It occurs in the umbilicus nearly exclusively in male infants (>90%); half of cases are diagnosed before the age of 8 months (range of age at diagnosis: 3-18 months). It may be an abnormal reparative process of the umbilicus. The condition is benign with no recurrences reported following a simple excision.

The polyp forms a dome-shaped or pedunculated umbilical elevation measuring 4-12 mm (median, 6 mm). Histologically, it may involve both dermis and deeper tissues containing relatively paucicellular, fibrocollagenous or fibromyxoid tissue with a slight resemblance to fasciitis or fibromatosis. Some lesions include fibroblasts with have ample cytoplasm and epithelioid features resembling similar cells in desmoid, or having a slight resemblance to ganglion cells. In contrast to true fibromatosis, blood vessels are not prominent. No epithelial elements, keloidal collagen or inflammatory component are present separating this lesion from pilonidal disease and keloid. This polyp is different from the umbilical polyps sometimes seen in older children and young adults. The polyp cells are often positive for (smooth muscle) actin, and some focally for desmin, and are negative for CD34, S100 protein, EMA, and keratins.

**Reference:**

Vargas SO. Fibrous umbilical polyp: a distinct Fasciitis-like proliferation of early childhood with a marker male predominance. Am J Surg Pathol 2001;25:1438-1442.

# AMR SEMINAR #59

## CASE 20

**Contributed by:** James Strauchen, M.D.

**History:** A 63-year-old man presented with an enlarging splenic mass and underwent laparoscopic splenectomy. No significant past medical history was available.

**Gross Pathology:** The spleen was received in morsels measuring from 0.4 to 3.3 cm and weighing 264 grams in total. No gross lesion was recognized, however, some of the morsels had a rounded, nodular configuration.

**Microscopic Pathology:** Sections showed the typical changes of sclerosing angiomatoid nodular transformation of the spleen. Immunohistochemical stains showed the vascular spaces within the nodules to be positive for CD31, CD34, and FVIIIr; negative for CD8, CD21/35, and CD68.

**Diagnosis:** Sclerosing angiomatoid nodular transformation (SANT) of the spleen.

**Comment:** This is not a diagnostic challenge, but I thought a very nice example of this lesion. This is the second case I have encountered in a laparoscopic splenectomy and still recognizable despite the morselized specimen. I did some immunohistochemical stains but they are not a requirement for the diagnosis. As I explained to the resident, this is one of those "how do you recognize your grandmother" type diagnoses.

**Reference:** Martel M, et al. Sclerosing angiomatoid nodular transformation (SANT): report of 25 cases of a distinctive benign splenic lesion. Am J Surg Pathol 2004; 18:1268-1279.

# AMR SEMINAR #59

## CASE 21

**Contributed by:** Saul Suster, M.D.

(Submitted by Dr. M. Nowacki, M.D., Baptist Hospital, Louisville, KY.)

**Clinical History:** The patient is a 25-year-old man who was seen 5 years ago for evaluation of a large anterior superior mediastinal mass. At the time, no mention of any other process was given. A core biopsy was obtained from the mass at the primary institution. The case was sent to me in consultation and, based on the history, the histology and results of IHC stains (essentially strong positivity for cytokeratins and CD3+ lymphocytes), I rendered a diagnosis of primary thymic epithelial neoplasm (thymoma with transition to thymic carcinoma). For some reason not stated, the patient was not treated and has now been readmitted with a 15 cm. left adrenal mass, which has been now resected. The case was once again submitted to me for a second opinion.

**Histologic Findings:** The current tumor in the adrenal gland is morphologically identical to the one in the previous mediastinal biopsy. It is composed of round to polygonal cells with abundant cytoplasm, except that in the adrenal material there are also areas displaying some spindling of the tumor cells. The tumor shows multiple cystic spaces as well as numerous mitoses, some of them abnormal and accompanied by nuclear pleomorphism. The results of the IHC stains done at various laboratories (original hospital, OSU, and now MCW) showed strong positivity of the tumor cells for vimentin, bcl-2, and focal positivity of the tumor cells for low-molecular weight cytokeratin (CK18) and CD99. CD3 showed many scattered small lymphocytes admixed with the epithelial cells. Stains for cytokeratin AE1/AE3, CK19, MOC31, inhibin, CD117, AFP, calponin, HBME-1, calretinin, and p63 were negative in the tumor cells. A FISH study for the SYT (X;18) translocation was negative.

**Diagnosis:** Poorly-differentiated malignant neoplasm with evidence of epithelial differentiation, NOS.

**Comment:** Obviously, I don't know what this tumor is. Equally obvious, my original interpretation of thymoma was incorrect. Although the morphologic appearance could be consistent with this diagnosis, I have yet to see a thymoma that did not show strong nuclear positivity for p63. The organoid, microcystic aspect of the tumor can be seen in a variety of entities, including thymoma, mesothelioma, meningioma, ovarian and adnexal neoplasms, and in germ cell tumors such as yolk sac tumor. But the immunohistochemical profile does not seem to fit for any of them. Other pathologists who have seen this case have proposed diagnoses that range from an unusual epithelioid synovial sarcoma to a primary adrenal carcinoma. The strong positivity for low-molecular weight CK's in this case, plus the negative staining for inhibin, would seem to speak against that diagnosis. But I would be interested to hear what other have to say, in particular our adrenal mavens. I would greatly appreciate the opinions of all the members on how they would handle this case.

# AMR SEMINAR #59

## CASE 22

**Contributed by:** Paul Wakely, Jr., M.D. (case 31146)

**History:** This 33-year-old white female had resection of a skull base meningioma at the age of 15 years, and has had a few resections since that time. She is now totally deaf in the left ear. Recently, she developed some left-sided headaches and evaluation shows a new mass in the infratemporal fossa and temporal bone. She completed 28 radiation therapy treatments prior to surgery. I apologize for the air under the coverslip due to the concretions (not a plastic coverslip) and histologic artifact in many slides.

**Diagnosis:** Meningioma, psammomatous variant.

**Comment:** The psammomatous histologic subtype of meningioma is considered low risk and is listed as a WHO grade I meningioma in contrast to the less common WHO grade II [clear cell, atypical and chordoid] variants, and WHO grade III [papillary, rhabdoid, and anaplastic] variants. Seven years after the resection of this mass which I signed out in 2003, I had the unfortunate experience of having to sign out this woman's primary colonic angiosarcoma in 2010. This has subsequently metastasized to her lung. I am not aware of any tumor syndrome in this patient (she does not have NF-1), nor am I aware of any association between colonic angiosarcoma and meningioma. Has anyone seen this combination before?

# AMR SEMINAR #59

## CASE 23

**Contributed by:** Paul Wakely, Jr., M.D. (case 44025)

**History:** A 62-year-old white male with papillary thyroid cancer (PTC) diagnosed 2 yrs. earlier presented with a right renal mass. Biopsy performed at an outside hospital read as papillary renal cell carcinoma (PRCC). Immunohistology from the outside slides showed immunoreactivity with cytokeratin AE1/3, cytokeratin 7, CD10, and EMA. Staining was negative for TTF-1, thyroglobulin, and cytokeratin 20. Nephrectomy showed an irregular mass occupying 2/3 of the kidney that was tan, friable, poorly circumscribed, and 7.2 x 5.8 x 4.5 cm. It did not involve the renal pelvis, nor was there extra-renal extension.

**Diagnosis:** Papillary thyroid carcinoma metastatic to the kidney mimicking a primary papillary renal cell carcinoma.

**Comment:** Immunohistology repeated in our lab showed diffusely positive TTF-1 and thyroglobulin staining in the tumor. Why these stains were negative in the biopsy specimen that led to an incorrect original diagnosis is unknown. This patient had widespread metastatic deposits to the skeleton. Trying to view this case from a pure morphologic standpoint and without knowing the patient's history or this tumor's immunophenotype, I think the distinction between PRCC, and PTC would be challenging indeed. In this slide, there is a lack of foamy macrophages within fibrovascular cores which is a characteristic, but not pathognomonic feature of PRCC. Nuclear grooves which are present here are seen in both neoplasms. The occasional multinucleated giant cell would suggest perhaps PTC, and some degree of nuclear stratification seen here might dissuade one from PRCC. Nonetheless, I would appreciate other club member opinions as to how they might tell the difference between these two tumors from an H&E alone. Also, has anyone seen an example of this?

Clinically detected metastatic well-differentiated thyroid carcinoma to the kidney is a rare event according to an article published by Liou et al. Their 2005 reference states that only 16 such cases had been reported, with a nearly even distribution between follicular and papillary thyroid CA subtypes. In a study of 1,739 renal allograft patients, Lee et al. found 12 (0.7%) with metastatic PTC. A review of 91 PTC patients with distant metastases by Hoie et al. does not mention any renal metastatic deposits, but states that 20 patients had "widespread metastatic disease involving several organ systems." Why the kidney remains relatively immune to PTC when it metastasizes outside the neck is unknown.

### References:

- Liou M-J et al. Renal metastasis from papillary thyroid microcarcinoma. *Acta Oto-Laryngologica* 2005; 125:438-42.
- Lee J, Jeong JJ et al. Incidence and clinical behavior of papillary thyroid carcinoma in renal allograft recipients: a single center experience. *Transplantation Proceedings* 2008;40:3751.
- Hoie J, Stenwig AE, et al. Distant metastases in papillary thyroid cancer. A review of 91 patients. *Cancer* 1988; 61:1-6.

# AMR SEMINAR #59

## CASE 24

**Contributed by:** Lawrence Weiss, M.D., City of Hope, Duarte, CA

**History:** 84- year old female with an enlarged spleen.

**Gross:** The spleen weighed 837 g and had a dominant mass.

**Immunos:** The atypical cells were weakly positive for CD43, and negative for CD163, CD3, CD20, CD21, CD23, CD335, and myeloperoxidase. The atypical cells were positive for S-100 protein and CD1a, yet negative for Langerin.

**EM:** No Birbeck granules identified.

**Molecular:** No Ig heavy or light or TCR gamma chain gene rearrangements detected.

**Diagnosis:** Indeterminate cell tumor of the spleen

**Discussion:** To my knowledge, this is the first case occurring in the spleen. It usually has been reported in the skin, and less commonly, lymph nodes. The cells look histiocytic/dendritic, but the phenotype is clearly dendritic. Note the lack of eosinophils. Indeterminate cells are defined by their S-100 +, CD1a +, yet Langerin – phenotype. The Langerin negativity correlates with the lack of Birbeck granules by EM. The clinical behavior of the lesion is still not clear, but it does not seem to be that aggressive a neoplasm.

### References:

Rezk SA, Spagnolo DV, Brynes RK, Weiss LM. Indeterminate cell tumor: a rare dendritic neoplasm. Am J Surg Pathol 2008, 32:1868-1876.

# **AMR SEMINAR #59**

## **QUIZ CASE 1**

**Contributed by:** Bruce M. Wenig, MD

**Clinical History:** 59-year-old male presented with an enlarging sublingual mass. The patient has no significant past history.